

Strange And Unpredicted Foreign Body Stories In ENT: As Peculiar case Presentations And Review Of Literatures

Khaled Mohamed bofares^{1*}, Zalfi Adim Haqqar² and Amna Fathi Ben Sasi³

¹professor of otorhinolaryngology, Omar Almoukhtar University, AL-Beyda city, Libya,

²Senior registrar, Al-Beyda medical center, AL-Beyda city, Libya.

³SHO, Al-Beyda medical center, AL-Beyda city, Libya.

Corresponding author:

Khaled Mohamed bofares,

professor of otorhinolaryngology, Omar Almoukhtar University, AL-Beyda city, Libya,

Roles of contribution

KMB: He is the first author, who was the professor and senior consultant that performed the procedures as well as completely wrote the manuscript. ZAH & AFB: they were the residents, who received the referred patients at the department, preparing them including history taking, complete clinical evaluation, requesting for required investigations, informed consent preparation, consultant on charge as well as operative theater team notification, postoperative care and follow up sessions conductance.

Received Date: 12 Sep 2024

Accepted Date: 01 Oct 2024

Published Date: 07 Oct 2024

Citation:

Khaled Mohamed bofares. Strange And Unpredicted Foreign Body Stories In ENT: As Peculiar case Presentations And Review Of Literatures. Annals of Clinical and Medical Case Reports 2024.

1. Abstract

Although the foreign body cases are considered as one of common urgencies and emergencies at ENT departments all over the world. These cases can be ranged from the life-threatening situations as in case of foreign body aspiration, to neglected foreign bodies as in cases of foreign bodies of nose and external auditory canal. It is commonly that the foreign body cases are presented among the extreme younger child-hood age group, and usually there will be a definitive history given by parents or guardians that indicating the diagnosis. However, sometimes the circumstance will become strange and surprising when the foreign body is discovered accidentally during the investigation for unpredicted complain, or when the patient is presented as adult age group with completely developed mental status. This was the scenario among our three case stories, those

showed amazing and odd history as well as clinical presentation, which encouraged and forced us to make this report just to highlight and focus on certain clinically applicable points regarding these unpredicted and forgotten issue.

Keywords:

strange foreign bodies, unpredicted foreign bodies, neglected foreign bodies, missed foreign bodies, accidental foreign bodies.

2. Introduction

The foreign bodies accidents are considered as one of urgencies and emergencies in the medicine as general and in the ENT specialty particular. This condition is considered as important issue because of its threatening effect on the victims' life particularly those of child-hood age group. The increase of the incidence of this condition in the community constitutes a worried indicator, which reflects the serious concerns as one of significant causes of sudden deaths among children. In addition, it can be used as a reliable indicator for the lack of proper child's care at the level of the family particular, and at the level of the population as general. The family negligence can be contributed by many factors as maternal education and literacy, family size, environmental sanitation, housing hygiene, and socio-economic status of the family [1], [2], [3], [4], and [5]. The foreign bodies' accidents outcomes range from minor morbidities, to sever morbidities, to life threatening circumstances and increasing the rate of mortalities. This is depending up on many factors as the site of the foreign body accident, the type of the foreign body and duration of foreign body staying. In accordance, the foreign bodies of the ear and nose usually are creating less morbidity as compared to foreign bodies of respiratory as well as alimentary tracts, which may lead to serious and fatal situations. On the other hand, the sharp foreign bodies and the corrosives bearing foreign bodies as the button batteries (disc batteries) may lead to more severe complications as compared to other types of foreign bodies. In addition, the duration of staying of the foreign body is considered as very significant determinant for its outcomes. However, this can correlated with the type of the foreign body i.e. for certain types of foreign bodies as corrosive chemicals bearing foreign bodies, the time factor has very important prognostic effect. The worseness of the prognosis is directly proportional to the prolongation of foreign body staying duration [3], [4], and [5].

There are well-established and customary facts regarding foreign bodies accidents, the foreign bodies accidents are commonly presented among extreme childhood age groups and mentally retardant adults, it is of lesser incidence rate among the normal adults. Although, there are certain varieties of foreign bodies accidents, which could be specifically

Annals of Clinical and Medical Case Reports

common at certain adult clusters as scarf pins among young women, the dentures among old ages, and esophageal food impaction among dentiless adults [6], [7], and [8]. The foreign bodies of the ear and the nose are usually easier to be diagnosed as compared to the respiratory as well as alimentary tracts foreign bodies. Moreover, the accidental discovering of the neglected aural as well as nasal foreign bodies is more predictable and reachable as compared to the missed aspirated and ingested foreign bodies [9]. There are well-established basics for the suggestion and diagnosis of foreign bodies aspiration and ingestion accidents. The history constitutes the most significant aspect for the diagnosis of foreign body aspiration as well as ingestion accidents. However, the clinical and the radiological findings are considered as complementary and secondary elements in favor of the diagnosis of these cases. In accordance, the clinical manifestations and the radiological findings may become of higher rate of significance if the foreign body was missed and the time of its staying was prolonged. The secondary effects of the missed foreign bodies can reason these clinical and/ or radiological findings. Moreover, among the patients with the missed respiratory tract foreign bodies, the presentation could be in form of persistent incurable pneumonia, bronchiectasis, and lung abscess, while in cases of missed alimentary tract foreign bodies, the manifestations might be in a clinical picture of unexplained dysphagia as well as odynophagia [21] and [22].

In the same context, it was noted that the missed foreign bodies usually discovered among extreme age groups, children at age below six years and elderly above sixty years. In addition, the discovering of missed foreign bodies among the mentally retarded people is very predictable. It is scarcity and unforeseen to discover a missed foreign body among intelligent and mature child or adult patient with well mental status [21], [22], and [23]. Thus, through this case series, we tried to postulate for the presentation of three situation of peculiar foreign bodies accidents with unpredicted and unique pattern of events, which cannot be suspected as they were presented with unusual scenarios. For this reason, we considered these three cases as important case series report for further new recommendations those can be obtained from this distinctive experience.

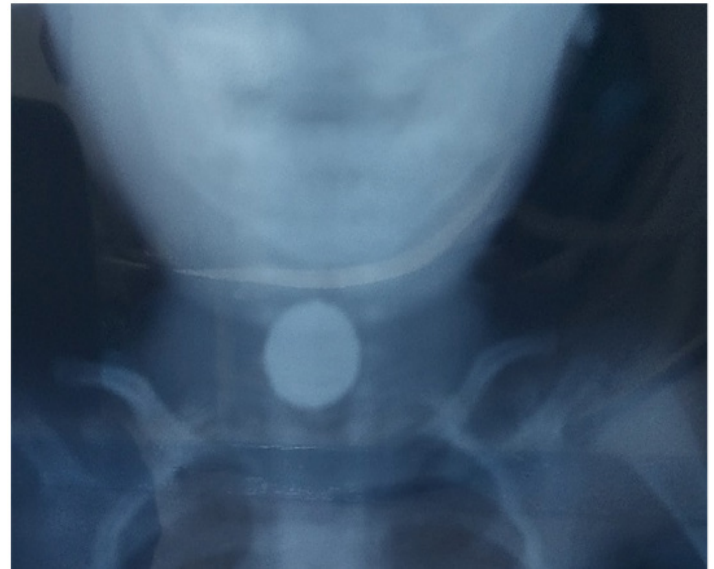
3. Cases presentations

3.1. Case-1:

Fifteen months old male Palestinian baby has been received by our resident SHO at our ENT department- Al-Beyda medical center, Al-Beyda city- Libya, as a referred case from pediatric department at the same center. The baby was accompanied with his parents, who presented the history. The main complaint was absolute dysphagia with drooling of saliva one day before the time of the reference. The mother noted the dysphagia five days before, as mild dysphagia that elucidated by the prolongation of the duration of the bottle-feeding more than usual. This was progressing along these five days to become severe at the fifth day with bothersome odynophagia and drooling of the saliva. The mother recognized the odynophagia by the crying of the baby during the swallowing process. During the first four days, the general practitioner

as a case of throat infection, treated the baby by oral antibiotic with synergistic oral decongestant and instead of his improvement, he became progressively worse. Thus, at the fifth day, the parents consulted the pediatrician, who asked for neck and chest conventional X-ray, where the tragedy was discovered. There was impacted large sized disc battery (button battery) at the level of crico-pharyngeal sphincter (Figure-1). In accordance, by the returning back to the parents with this positive X-ray finding, as the mother is known case of diabetes mellitus, she remembered that, few days back she lost the disc battery of her glucometer machine.

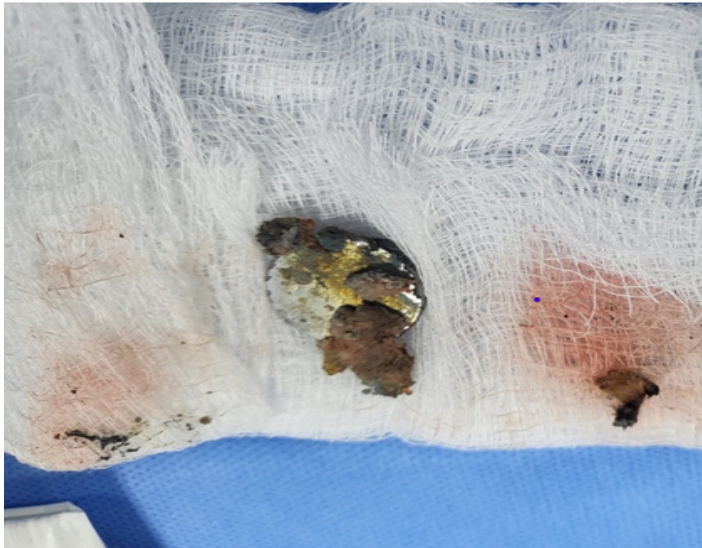
Figure-1: Conventional X-ray demonstration of the impacted foreign body at the level of crico-pharynx.



Therefore, the baby was decided for urgent rigid esophagoscopy, which was done under general anesthesia with endotracheal intubation and sufficient muscular relaxation. The rigid esophagoscope of size 8x12x25 was passed and the intraoperative findings were: A) There was foreign body in form of large sized disc battery recognized impacted at the level of crico-pharyngeal sphincter. B) The chemical material of the battery was found leaky out the battery to contaminate the wall and the lumen of the esophagus. C) The wall of the esophagus showed extensive and circumferential deep damage of the mucosa, extending up to the level of the muscular layer with brownish-black necrotic tissue (according to Zargar's classification of local esophageal damage by corrosive agents, it was graded as grade-IIIb). In the same context, our intervention was including: A) Recognition of the foreign body, grasped using the crocodile forceps and extracted (Figure-2). B) Theresiduals of the escaped chemical material were sucked out.C) The proper irrigation with sterile normal saline solution was done, associated with repetitive suction and clearance of the affected segment. D) After we made sure that the all-corrosive material was properly cleaned, the reassessment of the area was done to confirm the Zargar grade of the wall chemical injury. E) By the end, the nasogastric tube (NGT) was inserted under controlled as well as visualized field, and further proper fixation was done for it.

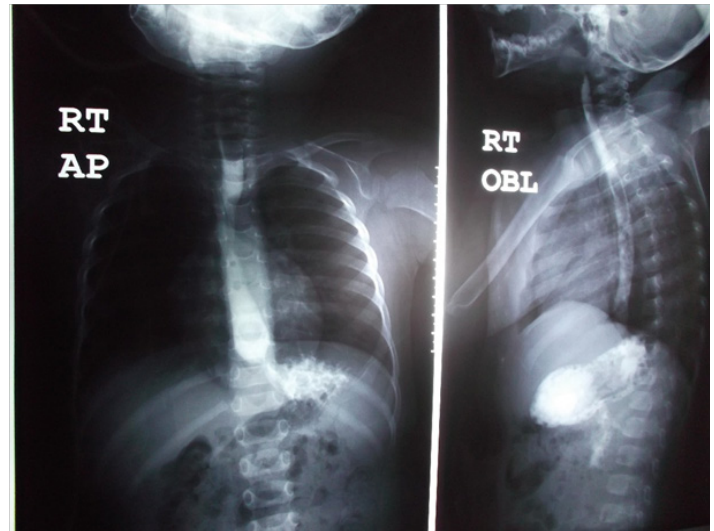
Annals of Clinical and Medical Case Reports

Figure-2: The extracted foreign body (disc battery), with escaped corrosive chemical material and sloughed necrotic soft tissue.



The postoperative care was according to the specific therapeutic protocol for three weeks, in form of: A) The patient kept as inpatient under closed observation that including body temperature, pulse rate, respiratory rate, systemic blood pressure, irritability, restlessness, and any pain onset. B) The patient kept on complete NGT feeding accompanied with daily IV fluids body requirements. C) The patient covered by combination of triple parenteral broad-spectrum antibiotics, which were amoxicillin with clavulanic acid, ceftriaxone, and metronidazole, 300mg/8 hourly, 250mg/12 hourly, and 125mg/8 hourly consecutively. D) In addition to the antibiotics, the baby kept on hydrogen-pump blocker (omeprazole) by IV route in a dose of 10mg once a day. In accordance, the mother was advised to encourage her baby to suck the antacid gel packages of fruity flavours every 6 hours frequency. E) Moreover, the baby was covered by antifungal oral suspension (Nystatin), three times a day. On the other hand, during the first week, the blood was extracted every 48 hours for leukocyte count, erythrocytes sedimentation rate (ESR), and C-reactive protein, in addition to the requesting for X-ray neck as well as chest. In same context, at the last two weeks, the previously mentioned investigations were done once per week. At the end of third week, the NGT was removed after frequent trials of oral fluids followed by semisoft diets. The baby was assessed clinically and radiologically to confirm the complete healing of the esophageal wall before the remove of NGT. After three months, the barium swallowing study was done to evaluate for any consequence esophageal segmental stricture or tracheo-esophageal fistula, which was free with complete normal flow of the barium (Figure-3). Last follow up session was after one year via which complete assessment of the child was done that showed a satisfied thrive status with normal feeding process, and no any significant complain from the parents.

Figure 3: The barium swallowing study, three months after the procedure, which illustrated a complete normal barium flow.



3.2. Case-2:

Seventeen years old Libyan girl presented with her parents as referred emergency case from casualty department to our ENT department- Al-Beyda medical center, Al-Beyda city- Libya with history of foreign body ingestion few hours before the time of her presentation. This was associated with sudden, abrupt history of absolute dysphagia bother some with severe odynophagia that interfere even with the swallowing of the saliva. In addition, there was history of repetitive attacks of vomiting of bloody stained secretions. The strange part of the story of this patient that the event was happened when the family members were sitting together during the dinner. There was one glass-cup broken and some of glass pieces dropped and mixed with food, and accidentally the patient during the eating she felt sharp object escaped from the oral cavity to her pharynx during the swallowing of the food. There was no other significant history apart of some element of psychological disturbance as noted by the parents in favor of depression psychopathy, but the patient had not been diagnosed or received any treatment before.

On examination, according to visual analogue scale (VAS) the patient was in severe pain with evidence of neck rigidity. There was excessive drooling of the saliva with absolute dysphagia. No evidences of subcutaneous emphysema, or tenderness at any part of the neck. The X-ray neck revealed evidences of neck spasm that indicated by the loss of normal cervical lordosis. In addition, there was clear evidences of significant dilation of the upper part of the esophagus with illustrated air bubbles at the dilated segment. Therefore, accordingly the patient decided for esophagoscopy procedure under general anesthesia, which done as emergency intervention by passing the rigid esophagoscope of size 12x16x35. The intraoperative findings and procedures were: A) There was evidences of pooling of the saliva. B) there was small mucosa abrasion at the posterior pharyngeal wall, which constitutes the source of the bleeding as complained by the patient. C) The foreign body was recognized at the level of aortic sphincter (around 25cm from the incisor teeth), it was piece of transparent glass. D) The foreign body grasped gently with peanut

Annals of Clinical and Medical Case Reports

forceps (the crocodile forceps may crush the foreign body) and extracted out under the protection of the esophagoscope itself (Figure-4). E) The esophagoscope of the same size was re-passed again just to assess for any injuries, there was no evidences of any injuries due to maneuvering of the foreign body.

Figure-4: The extracted foreign body (piece of glass).



On the other hand, the patient was kept in the ward under postoperative care protocol that including: A) Early oral feeding just after full recovery. B) Oral administration of amoxicillin with clavulanic as broad-spectrum antibiotic in a dose of 1000mg 12 hourly. C) Complete restriction of analgesics as well as antipyretics administration. D) The patient kept in the ward for 24 hours for close observation, and after post-procedure evaluating neck and chest X-ray, she was discharged in satisfied best conditions and completely normal swallowing function.

3.3. Case-3:

Eleven years old female Libyan child had been presented as a referred case from the pediatrician with history of persistent productive cough as bothersome manifestation of recalcitrant right lung broncho-pneumonia that not responding to the treatment. There was history of attacks of fever and wheezy chest associated with exertional dyspnea, from three months ago. On the examination of the chest, the auscultation findings revealed harsh bronchial breathing sound at the right side of the chest associated with rhonchi and crepitations scattered all over the right side of the chest. In addition, the intensity of the breathing sound is decreased at the affected side as compared to the other side. On the other hand, the radiological evaluation by conventional chest X-ray revealed a picture of broncho-pneumonia with scattered radio-opaque patchy illustration.

Therefore, the clinical as well as the radiological presentation gave to us the high suggestion of the missed foreign body aspiration. Thus, we return to the parents and child herself to ask them directly about any history of foreign body aspiration or choking, unfortunately the answer was negative. Surprisingly, after few minutes, the child suddenly shouted to confirm a positive history of choking with the plastic pen-head, when

she was playing with it at her mouth during the writing of her homework alone at her room from three months ago, which is the same time of the beginning of her illness. However, the patient ignored this event at that time, and did not tell her parents about this history. In accordance, up to that moment, the diagnostic bronchoscopy became absolutely indicated, which was decided as emergency procedure under general anesthesia. The patient was intubated by rigid bronchoscope of size 5mm and it was a surprise, the foreign body was seen. It was the plastic pen-head, of blue color, impacted at right main bronchus. The foreign body was removed using crocodile forceps (figure-5). The rinsing of accumulated mucopurulent secretions was done. The child was recovered in complete good status; she did not need additional intensive care. Moreover, the child was kept postoperatively at the ward just for control of her chest infection by parenteral administration of ceftriaxone in a dose of 500mg/ 12hourly; in addition to orally administered bronchodilator as well as mucolytic syrups. The patient stayed in the hospital for two days, and after that she was discharged in good conditions to continue her treatment as out patient.

Figure-5: The extracted foreign body (plastic pen-head).



4. Discussion

Although, the foreign body accidents are considered as one of the common emergency conditions at the world as general and at our society particular. However, these three cases can be described as unique and peculiar cases as compared to the other usual cases of foreign body accidents. Regarding the first case, it is surprisingly that the large sized disc battery stayed in the esophagus for five days with escaped its corrosive material and did not cause the perforation of the esophageal wall. Scientifically speaking, this could be explained by one fact only that the battery's material is already expired. This fact can be confirmed and correlated with the history, which was given by the mother that the swallowed disc battery was missed after she removed it from her glucometer to be changed by new one. On the other hand, it is surprisingly that how this case was missed for all this period and no body suggest the possibility of foreign body ingestion, especially when this baby presented with absolute dysphagia with

Annals of Clinical and Medical Case Reports

completely normal throat.

The disc battery (button battery) is considered as one of most dangerous foreign bodies. This is because of its extensive destructive effect due to the electrical as well as the corrosive chemical action. Therefore, the disc battery foreign bodies once diagnosed anywhere; they should be extracted as soon as possible. It was found that the severity of the destructive effect of this kind of foreign bodies is directly proportional to the duration of its negligence. In same context, it was established that the safety zone of the staying duration of this type of foreign bodies should not exceed two hours [10], [11], [12], [13], [14], [15], and [16]. In accordance, the diagnosis of the disc battery ingestion can be illustrated by the conventional X-ray, which will show characteristic appearance of radiolucent rim surrounding the disc of the battery (figure-6) [14], [15], [16], and [17]. On the other hand, after the remove of this variety of the foreign bodies from the esophagus, the proper cleaning and rinsing of the area should be done by repetitive normal saline irrigation and suction [16], [17], [18] and [19]. This should be followed by proper assessment of the esophageal wall and grading of the injury according Zargar's grading system [20]. The insertion of NGT should be taken as rule in our management protocol whenever there evidences of esophageal wall injury (from grade-I to grade-IV) [16], [17], [18], [19] and [20]. The NGT insertion is important to achieve these three aims: 1) The complementary feeding process to the parenteral nutrition. 2) The drainage of the gastric juice for the purpose of the prevention of its reflux that may increase the severity of the injury and interfere with the proper healing process. 3) The NGT is used as stent for the esophageal lumen to allow the healing without strictures formation.

The NGT will be kept for 14-21 days; this is the recommended duration for NGT in the cases of corrosive esophageal traumas, which was found to be sufficient for satisfied outcomes[10], [11], [12], [13], [14], [15], [16],[17], [18], [19] and [20]. In addition, as a part of the management of these cases, the patients should be kept on certain post-procedure medications, which include: 1) Broad-spectrum antibiotics, these are important to control any possible local superadded infection at the site of the injury, which may make the condition more badly. In addition, the broad-spectrum antibiotics are prophylactic against mediastinum infection spreaders. 2) Antacids, which are important to neutralize the secreted gastric acid that may refluxed to the esophagus and propagate the severity of the destructive effect of the corrosive injury. 3) H- pump blocker, it has the same role of antacids by blocking of the production of gastric acid and therefore it reduces the risk of the esophageal reflux. 4) Local antifungal agents, these are important to provide a sufficient prophylaxis against possible fungal flaring-up as the adverse effect of the long-term administration of broad-spectrum antibiotics. 5) Certain vitamins supplement, namely vitamin A, E, in addition to iron, which found to be very helpful for enhancement of healing process[17], [18], [19] and [20].

For extreme young ages (< 3 years), and as the patient kept for three weeks on NGT feeding, thus, there are certain physiological reflexes namely sucking reflex, gag reflex, chewable reflex and swallowing reflex, in

addition to the gustatory perception as well as salivation secretion, which should be maintained. This may need to advice the mother to encourage her kid for daily frequent sessions of suckings. In accordance, as I noted from my experience, the best choice is the administration of antacids oral gels with different fruits flavors. This will give us the chance to achieve two goals, the first is the obtaining of the antacid effect to neutralize the refluxed gastric acid, and the second to maintain all those mentioned physiological reflexes[10], [11], [12], [13], [14], [15], and [16]. On the other hand, by three to six months after corrosive agents' esophageal traumas, the patients should be evaluated by barium swallowing study to rule out any evidence of local healing with strictures. In the same context, if there are clinical manifestations suggestive esophageal strictures the diagnostic fibro-optic esophagoscopy may be indicated[10], [11], [12], [13], [14], [15], and [16].

Although, many literatures stated that the most important aspect for the diagnosis of the foreign body aspiration accidents is the presence of the definitive history. In contrary, as we can elucidate from our experience that the history of definitive foreign body aspiration is not always considered for the diagnosis, sometimes the history is ignored or hidden. The part of the history, which may remain significant at this circumstance, is of the persistence of the respiratory symptoms that resist to the treatment[21], [22], [23], [24], [25], [26], and [27]. Therefore, we may consider the diagnostic bronchoscopy as a part of the patient evaluation, who presented with refractory respiratory manifestations despite of sufficient medical treatment [24], [25], [26], [27], [28], [29], and [30]. In accordance, the same recommendation can be applied for those patients, who manifested with persistent symptomology after extraction of the foreign bodies of the respiratory tract just to exclude the missed residual foreign bodies. In accordance, the missed foreign bodies bronchimight be misdiagnosed as asthma, due to the chronicity of the manifestations as well as the resembling of the clinical data to those among asthmatic patients[27], [28], [29], and [30]. On the other hand, the neglected foreign bodies bronchi may become difficult to be extracted under the endoscopic control techniques, because of their deep impaction. At this moment, the extensive surgical techniques via opened thoracotomy approaches will be only the choice[22], [23], and [24].

Moreover, for the young patients, who presented with sharp foreign bodies ingestion accidents, we should exclude the suicidal attempt conditions [31], [34], [35], [36], [38], [39], [40] and [41]. Thus, the socio-psychological assessment for those varieties of patients should be considered as a part of their management [32] and [33]. In addition, from technical point of view, for the patients, who presented with sharp foreign bodies ingestion accidents, the esophagoscopy procedure can be performed as rigid or flexible types. However, as we concluded from our long-term experience that the rigid esophagoscopy technique will be preferred as compared to the flexible esophagoscopy technique. This is reasoned by the providing of a sufficient wide access for a safe extraction of the sharp foreign bodies by its entrapment in the lumen of the rigid esophagoscope itself to protect the esophageal walls. Therefore, the size of the used rigid esophagoscope

should the maximum suitable size.

5. Ethical approval

The endorsement and statistical department at AMC- AL-Beyda city-Libya ethically approved the publication of this case.

6. Acknowledgement

We would like extremely thanks the parents/ guardians of those presented children, who gave use the agreement to publish these unique cases.

Ethical aspects

The patients' parents'/guardians' informed consent was obtained both for the procedures performance and for the authorization of the publication of the clinical cases.

References

- Fahad Alamr,etal. Prevalence and Risk Factors of Home Accidents Among Children Under Five Years of Age in Al-Baha, Saudi Arabia. *Cureus*. 2023 Oct; 15(10): e46846.PMCID: PMC10637285. PMID: 37954756
- Catherine S Birken and Colin Macarthur. Socioeconomic status and injury risk in children. *Paediatrics & Child Health*. June 2004; 9(5):323-5.
- Suk Jin Hong, et al. Foreign body ingestion trends in children in the Daegu-Kyungpook Province, Korea before and during the COVID-19 period: a repeated cross-sectional study. *Translational pediatrics*. July 2023; Vol (12). NO.7.
- Gummin DD, Mowry JB, Beuhler MC, et al. 2020 Annual Report of the American Association of Poison Control Centers' National Poison Data System (NPDS): 38th Annual Report. *Clin Toxicol (Phila)* 2021;59:1282-501. [Crossref] [PubMed]
- Salman H, Gürsoy Koca T, Dereci S, et al. Foreign Body Ingestion and Management in Children. *Pediatr Emerg Care* 2022;38:617-20. [Crossref] [PubMed]
- Huseyin C, Mustafa A. Foreign Bodies Ingested by a Mentally Retarded Patient. *Turk J Emerg Med*. 2015 Jun; 15(2): 57.doi: 10.5505/1304.7361.2014.34635. PMCID: PMC4909982. PMID: 27336063
- Cire Ndiaye, et al. An Unusual Laryngeal Foreign Body in Adult. *Case Rep Otolaryngol*.2016 Nov 23. doi: 10.1155/2016/5798070. PMCID: PMC5141548. PMID: 27999701
- Gencer M., Ceylan E., Koksall N. Extraction of pins from the airway with flexible bronchoscopy. *Respiration*. 2007;74(6):674–679. doi: 10.1159/000102302. [PubMed] [CrossRef] [Google Scholar]
- Joshua Garg, Francis De Castro, Paramesh Puttasidiah. Ear, Nose, and Throat Foreign Bodies in the Paediatric Population: Did the COVID-19 Lockdown Change Anything?. *Cureus*. 2022 Aug; 14(8): e27892.doi: 10.7759/cureus.27892. PMCID: PMC9464042. PMID: 36110438
- Richard K. Newman; Bjorn Dijkstra; Joshua Gibson. Disc battery ingestion. National library of medicine. 2023 Aug 14. In: StatPearls [Internet]. Treasure Island (FL): StatPearls Publishing; 2024 Jan. PMID: 29262219
- Cohen WG, Mchugh M, Giordano T, Jacobs IN.Anatomic Considerations of esophageal button battery ingestion for outcomes and imaging.Int J Pediatr Otorhinolaryngol. 2024 Jan;176:111803. doi: 10.1016/j.ijporl.2023.111803. Epub 2023 Nov 24.PMID: 38043185
- Kiefer A, Duppel U, Schützenmeier A, Lang T, Kittel J, Kabesch M, Kerzel S.Button Battery Ingestions cause the Majority of Severe Complications.Klin Padiatr. 2023 Mar;235(2):90-97. doi: 10.1055/a-2007-1686. Epub 2023 Feb 9.PMID: 36758576
- Scalise PN, Durgin JM, Staffa SJ, Wynne N, Meisner J, Ngo P, Zendejas B, Kim HB, Demehri FR.Pediatric button battery ingestion: A single center experience and risk score to predict severe outcomes.J Pediatr Surg. 2023 Apr;58(4):613-618. doi: 10.1016/j.jpedsurg.2022.12.017. Epub 2022 Dec 22.PMID: 36646540
- Ohns MJ.Button Battery Ingestion: A Case Report.J Pediatr Health Care. 2022 Sep-Oct;36(5):465-469. doi: 10.1016/j.pedhc.2022.06.003. Epub 2022 Jul 14.PMID: 35843853
- Lorenzo C, Azevedo S, Lopes J, Fernandes A, Loreto H, Mourato P, Lopes AI.Battery Ingestion in Children, an Ongoing Challenge: Recent Experience of a Tertiary Center.Front Pediatr. 2022 Apr 27;10:848092. doi: 10.3389/fped.2022.848092. eCollection 2022. PMID: 35573958
- Wang HC, Hu SW, Lin KJ, Chen AC.A novel approach to button battery removal in a two-and-half year-old patient's esophagus after ingestion: a case report.BMC Pediatr. 2022 Feb 17;22(1):96. doi: 10.1186/s12887-022-03142-3.PMID: 35177027
- Pérez-Martínez A, Molina-Caballero A, Goñi-Orayen C.Impaction of button batteries in the esophagus: a potentially fatal surgical emergency in infancy.An Sist Sanit Navar. 2020 Aug 31;43(2):255-260. doi: 10.23938/ASSN.0874.PMID: 34978548
- Peter Ernest Kipiki, Desderius Chussi, Peter Shija, Francis Kimwaga, Adnan Sadiq, Kenneth Mlay. Button battery ingestion: A serious pitfall of diagnosis of ingested foreign bodies in children from resource-limited settings – A case report. *International Journal of Surgery Case Reports*. Volume 109, August 2023, 108593
- Johannes Voelker, Christine Voelker, Joachim Voelker, Jonas Engert , Phillipp Schendzielorz , Rudolf Hagen , Kristen Rak. Button batteries and typical swallowed foreign bodies can be differentiated in high-resolution X-Rays. *Pediatric otorhinolaryngology*. Volume 142, March 2021, 110604
- Yu-Jhou Chen, et al. Evaluation of a Diagnostic and Management Algorithm for Adult Caustic Ingestion: New Concept of Severity Stratification and Patient Categorization. *J. Pers. Med*. 2022, 12(6), 989; https://doi.org/10.3390/jpm12060989
- Sanjivani J Keny and Uday C Kakodkar. A forgotten foreign body

Annals of Clinical and Medical Case Reports

- in bronchus. *Lung India*. 2016 Nov-Dec; 33(6): 694–696. doi: 10.4103/0970-2113.192854
22. Ahmed A Bahnassy, and Abdul Basset Diab. Neglected Bronchial Foreign Body in a Child Simulating a Calcified Mass Lesion: Challenging Computed Tomography Diagnosis. *Int J Health Sci (Qassim)*. 2007 Jan; 1(1): 107–109. PMID: PMC3068660, PMID: 21475459
 23. Mohammad Ashkan Moslehi , and Alireza Mohamadian. Diagnosis of a missed bronchial foreign body in an 8-year-old girl: a rare case report. *Qatar Med J*. 2021; 2021(1): 6. Published online 2021 Feb 22. doi: 10.5339/qmj.2021.6. PMID: PMC7903518, PMID: 33680878
 24. Ishan Jhalani, Anshuman Darbari, Mayank Mishra, Pradeep Kumar. Surgical retrieval and successful bronchial repair for impacted foreign body: a case report. *EJB* 16, Article number: 67 (2022).
 25. Newby MD, Thomas D, Mullett CJ, Vijay C, Carr MM. Foreign body aspiration presenting as pneumothorax in a child. *Cureus*. 2020;12(5):e8161. [PMC free article] [PubMed].
 26. Nagendra Chaudhary, Sandeep Shrestha, Om P. Kurmi. A child with a foreign body in bronchus misdiagnosed as asthma. *Clin Case Rep*. 2020 Dec; 8(12): 2409–2413. Published online 2020 Jul 21. doi: 10.1002/ccr3.3153. PMID: PMC7752614. PMID: 33363751
 27. Yingchao Zhu, Qijun Fan, Lijun Cheng, Bobei Chen. Diagnostic Errors in Initial Misdiagnosis of Foreign Body Aspiration in Children: A Retrospective Observational Study in a Tertiary Care Hospital in China. *Front Pediatr*. 2021; 9: 694211. Published online 2021 Oct 15. doi: 10.3389/fped.2021.694211. PMID: PMC8555661. PMID: 34722414
 28. Bo Liu, Fengxia Ding, Yong An, Yonggang Li, Zhengxia Pan, Gang Wang, Jiangtao Dai, Hongbo Li & Chun Wu. Occult foreign body aspirations in pediatric patients: 20-years of experience. *BMC Pulmonary Medicine* volume 20, Article number: 320 (2020).
 29. Luis Alejandro Rodríguez Hidalgo, Luis Alberto Concepción-Urteaga, Julio Hilario-Vargas, Jorge Luis Cornejo-Portella, Diana Cecilia Ruiz-Caballero, Deysi Leslie Rojas-Vergara. Case report of recurring pneumonia due to unusual foreign body aspiration in the airway. *Medwave* 2021;21(02):e8136 doi: 10.5867/medwave.2021.02.8136.
 30. Lina Wang, MM, Li Zhang, MM, Chunyan Li, MD, Hang Liang, MM, Deli Li, MM, Yan Wang, BA, Xin Yin, MM, Dawei Ren, MM, Xiangfeng Meng, BA, Fanzheng Meng, MD. Characteristics of correct diagnosis versus misdiagnosis of paediatric tracheobronchial foreign body. *Paediatrics & Child Health*, Volume 26, Issue 1, February 2021, Pages e6–e10, <https://doi.org/10.1093/pch/pxz128>.
 31. Fariha Bangash, James L Megna, Luba Leontieva. Deliberate Foreign Body Ingestion in a 35-Year-Old Woman With Borderline Personality Disorder and Several Psychiatric Comorbidities. *Cureus*. 2021 Feb; 13(2): e13179. Published online 2021 Feb 6. doi: 10.7759/cureus.13179. PMID: PMC7885791. PMID: 33643751
 32. Arne Jorma Speidel, Lena Wölflé, Benjamin Mayer, Carsten Posovszky. Increase in foreign body and harmful substance ingestion and associated complications in children: a retrospective study of 1199 cases from 2005 to 2017. *BMC Pediatr*. 2020; 20: 560. Published online 2020 Dec 18. doi: 10.1186/s12887-020-02444-8. PMID: PMC7747382. PMID: 33339520
 33. Soham Shah, and Attila Nemeth. Foreign Body Ingestion: An Unusual Case in a Patient with Dementia. *Cureus*. 2023 Jun; 15(6): e41212. PMID: PMC10387322, PMID: 37525804
 34. Baker J, Beazley PI. Judging personality disorder: a systematic review of clinician attitudes and responses to borderline personality disorder. *J Psychiatr Pract*. 2022;28(4):93–175.
 35. Leichsenring F, Heim N, Leweke F, et al. Borderline personality disorder: a review. *JAMA*. 2023;329(8):9–670.
 36. 36- Stoffers-Winterling JM, Storebø OJ, Pereira Ribeiro J, et al. Pharmacological interventions for people with borderline personality disorder. *Cochrane Database Syst Rev*. 2022; 11:CD012956.
 37. Becq A, Camus M, Dray X. Foreign body ingestion: dos and don'ts. *Frontline Gastroenterology*. 2021;12(7):664–670.
 38. Gitlin DF, Caplan JP, Rogers MP, et al. Foreign-body ingestion in patients with personality disorders. *Psychosomatics*. 2007;48(2):162–166.
 39. Parisa Divsalar, Soudabehsadat Hosseini Mousa, Mehdi Hayatbakhsh Abbasi. Repeated Intentional Swallowing of Foreign Objects by an Adolescent Girl (Case Report). *International Journal of High Risk Behaviors and Addiction*. April 2023; Vol.12, issue 2; e134720. DOI: <https://doi.org/10.5812/ijhrba-134720>.
 40. Wimberley T, MacCabe JH, Laursen TM, Sorensen HJ, Astrup A, Horsdal HT, et al. Mortality and Self-Harm in Association With Clozapine in Treatment-Resistant Schizophrenia. *Am J Psychiatry*. 2017;174(10):990–8. [PubMed ID: 28750580]. <https://doi.org/10.1176/appi.ajp.2017.16091097>.
 41. Gitlin DF, Caplan JP, Rogers MP, Avni-Barron O, Braun I, Barsky AJ. Foreign-body ingestion in patients with personality disorders. *Psychosomatics*. 2007;48(2):162–6. [PubMed ID: 17329611]. <https://doi.org/10.1176/appi.psy.48.2.162>