

# Acute Kidney Injury As A Rare Side Effect of Pyrazinamide

**B. Badri\*, C. Jellal, S. El Morabit, N. Reguig, S. Diani, M. Aharmim and Je. Bourkadi**

Pulmonology-Phtisiology department, Hopital Moulay Youssef, CHU Ibn Sina Rabat

## Correspondence:

B. Badri,  
Pulmonology-Phtisiology department, Hopital Moulay Youssef, CHU Ibn Sina Rabat

**Received Date:** 02 Sep 2024

**Accepted Date:** 16 Sep 2024

**Published Date:** 22 Sep 2024

## Citation:

B. Badri. Acute Kidney Injury As A Rare Side Effect Of Pyrazinamide. Annals of Clinical and Medical Case Reports 2024.

## 1. Introduction

An appropriate antituberculous regimen is the most effective means of stopping the spread of the tuberculosis epidemic, ensuring that the disease is contained and managed effectively. However, while these regimens are crucial, they are not without risks. Acute kidney injury (AKI) is a rare but severe complication associated with antituberculous drugs. This condition can lead to significant health issues, potentially progressing to chronic renal failure. In extreme cases, severe acute renal failure can result in death, underscoring the need for careful monitoring and management of patients undergoing these treatments.

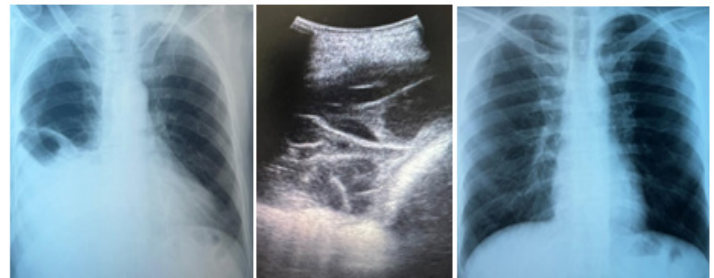
## 2. Case Report

We present the case of an 18-year-old patient with a history of occasional smoking, now ceased. The patient was being treated for pleural tuberculosis, clinically diagnosed based on a combination of indicators :

- Pleural effusion: exudate with lymphocytic predominance
- Pleural ADA > 40
- Recent tuberculosis exposure

The patient was prescribed a weight-adjusted antituberculous regimen, starting 2 months of intensive phase : Rifampicin (R), Isoniazid (H), Pyrazinamide (Z) and Ethambutol (E), followed by 4 months of Rifampicin (R) and Isoniazid (H). On the 13th day of the antituberculous treatment, the patient developed severe abdominal pain, particularly in the flanks, which was resistant to symptomatic treatment and was accompanied by nausea and vomiting. The physical examination was unremarkable except for abdominal tenderness with a negative lumbar contact.

Biological tests revealed severe acute renal failure with a creatinine level of 42 mg/L (compared to 6.3 mg/L before the start of treatment) and an estimated glomerular filtration rate (eGFR) of 19 ml/min/m<sup>2</sup>. The rest of the test results were normal. A comprehensive nephrological workup was conducted (including urinary ionogram, urine culture, 24-hour proteinuria), which returned unremarkable results. A renal-bladder-prostate ultrasound showed a slight increase in the size of both kidneys. The antituberculous treatment dosage was adjusted according to the patient's renal function (eGFR), with a gradual reintroduction of individual drugs, followed by renal function monitoring after each reintroduction. The results indicated that renal function remained normal after reintroducing Ethambutol (E), Isoniazid (H), and rifampicin (R). However, creatinine levels increased again after reintroducing Pyrazinamide (Z), confirming Pyrazinamide as the cause of the acute renal failure. The recommended treatment regimen in this case was adjusted 2RHE/7RH while removing Pyrazinamide, associated with respiratory physiotherapy resulting in favorable clinical and biological outcomes, evidenced by weight gain, resolution of pleural effusion and stable renal function throughout the treatment period.



## 3. Discussion

Acute kidney injury due to antituberculosis drugs accounts for approximately 1% of tuberculosis drug-related complications according to literature data [1]. The risk of such involvement, albeit rare, is irreversible chronic renal failure or even death from severe acute renal insufficiency in extreme cases. The most likely renal involvement reported in the literature is acute immuno-allergic interstitial nephritis, with a primary risk factor being previous exposure to the implicated molecule and discontinuation of treatment [1-3]. Studies published on this matter predominantly implicate Rifampicin as the molecule posing the highest risk, responsible for the majority of reported cases of renal failure [1-4].

The onset of acute renal involvement secondary to antituberculosis treatment appears during the intensive phase of treatment across studies but at varying time intervals. Sakashita et al.'s study, encompassing 15 patients, found a range between 21 and 54 days [1], while Chang et al., in a study involving 60 patients, observed onset ranging from 20 to 105 days from the initiation of antituberculosis treatment [5]. In our case, the shortest observed interval was 13 days. Acute renal involvement secondary

# Annals of Clinical and Medical Case Reports

to Pyrazinamide, as in our case, is extremely rare. To our knowledge, only a few isolated cases have been published in the literature over two decades ago, notably those by Sanwikarja et al. in the Netherlands [6] and Namba et al. in Japan [7]. Therapeutic alternatives vary from case to case, depending on several factors including the location and severity of tuberculosis involvement.

## 4. Conclusion

The nephrotoxicity of antituberculosis drugs, especially Pyrazinamide, is an underreported side effect in literature. The aim of this publication is to raise awareness among healthcare professionals about this rare but serious complication during the course of antituberculosis treatment.

## References

1. K, Sakashita et al. A case series of acute kidney injury during anti-tuberculosis treatment. *Intern Med.* 2019 Feb 15; 58(4): 521–527.
2. Beebe A et al. Rifampicin-induced nephrotoxicity in a tuberculosis patient. *J Clin Tuberc Other Mycobact Dis.* 2015 Oct 24;1:13-15
3. Muthukumar T, Jayakumar M, Fernando EM, Muthusethupathi Ma. Acute renal failure due to rifampicin: a study of 25 patients. *AmJ Kidney Dis* 40: 690-696, 2002.
4. Schubert et al. Acute tubulointerstitial nephritis related to antituberculous drug therapy. *Clinical Nephrology.* 2010 Jun;73(6):413-419
5. Chang CH, Chen YF, Wu VC, Shu CC, Lee CH, Wang JY, Lee LN, Yu CJ. Acute kidney injury due to anti-tuberculosis drugs: a five-year experience in an aging population. *BMC Infect Dis.* 2014 Jan 13;14:23. doi: 10.1186/1471-2334-14-23. PMID: 24410958; PMCID: PMC3898246.
6. Sanwikarja S, et al. Tubulointerstitial nephritis associated with pyrazinamide. *Neth J Med.* 1989 Feb;34(1-2):40-6.
7. Namba S et al. A case of pyrazinamide-associated myoglobinuric renal failure. *Jpn Med.* 1991 Sep-Oct;30(5):468-72.