

Case of Successful Treatment of Acute Respiratory Distress Syndrome in The Parturient Woman With Systemic Lupus Erythematosus and Cerebral Cyst of The Third Ventricular Complicated By Posterial Reversible Encephalopathy Syndrome

Kristina Bykova*, Igor Kasherininov, Andrey Bautin and Irina Savvina

Almazov National Medical Research Centre, St. Petersburg, Russia

*Corresponding author:

Kristina Bykova, MD,
Almazov National Medical Research Centre, St. Petersburg, Russia.
Tel: +7-920-456-00-48;

Received Date: 17 May 2023

Accepted date: 03 June 2023

Published Date: 17 July 2023

1. Abstract

Pregnancy and the postpartum period provoke an exacerbation of systemic lupus erythematosus (SLE), which requires aggressive cytostatic therapy that can cause life-threatening conditions for the fetus and complications for the mother, one of which is posterior reversible encephalopathy syndrome (PRES-syndrome). The article describes a clinical case of successful treatment of acute respiratory distress syndrome (ARDS) in a 22-year-old woman in labor with high activity of SLE during pregnancy complicated by the development of PRES-syndrome. Also, for the first time in the postpartum period, the patient was diagnosed with occlusive triventricular hydrocephalus, a giant cyst of the third ventricle. An emergency endoscopic cystoventriculocisternostomy was performed. In the future, the development of severe ARDS against the background of sepsis, which required the setting of extracorporeal membrane oxygenation (ECMO). A multidisciplinary approach and timely therapy saved the life of a young mother.

2. Editor

We report the case of successful treatment of acute respiratory distress syndrome (ARDS) in the 22-year-old woman with high activity of systemic lupus erythematosus (SLE) during pregnancy complicated by development of posterior reversible encephalopathy syndrome (PRES). Patient B., 22 years old, primiparous, was hospitalized to the Almazov National Medical Research Centre due to severe respiratory failure

against the background of an increase in hydrothorax, hydropericardium. She was receiving prednisolone 30 mg/day and rituximab 1000 mg for life in combination with plaquenil at 28 weeks of gestation due to treatment of SLE. Conducted pulse therapy with methylprednisolone 1000 mg per day for 3 days, also conducted antibacterial, anticoagulant, magnesium, antihypertensive therapy with a positive effect.

Due to the deterioration of the fetal condition, an emergency caesarean section was performed at 28 0/7 weeks, cytostatic therapy with cyclophosphamide in dose 1000 mg was continued. Generalized convulsive seizure suddenly was developed on the 1st day after delivery. Magnetic resonance imaging (MRI) of the brain revealed changes in the subcortical-cortical structures of the occipital and temporal lobes, verified as PRES; occlusive triventricular hydrocephalus, giant cyst of the third ventricle see figure 1.

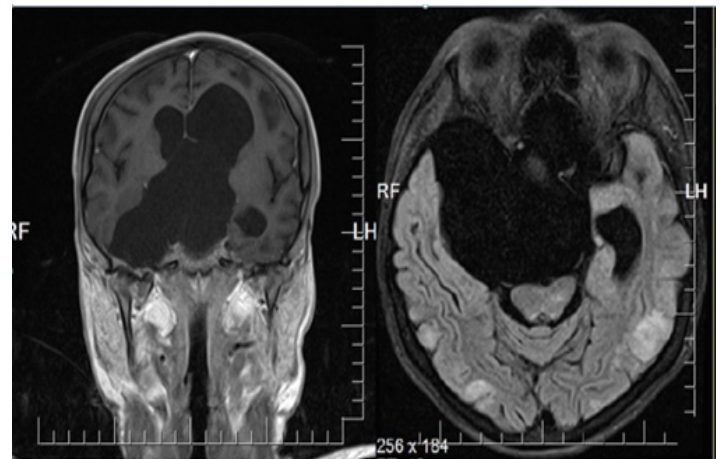


Figure 1: MRI of the brain of the patient B., 22 y. o. Occlusive triventricular hydrocephalus, giant cyst of the third ventricle, PRES syndrome.

An emergency endoscopic cystoventriculocisternostomy was performed. On the first day after neurosurgical intervention, respiratory failure rapidly progressed, requiring intubation and mechanical ventilation. Chest computed tomography (CT) demonstrated massive zones of infiltration in the lungs, left-sided hydrothorax, hydropericardium. In dynamics, after 3 days, extensive areas of ground glass were appeared in the upper lobes of both lungs, zones of interstitial edema were formed, and manifestation of polyserositis was increased. We diagnosed severe ARDS

Annals of Clinical and Medical Case Reports

of mixed etiology (sepsis, SLE - lupus pulmonitis, bilateral nosocomial pneumonia) see figure 2.

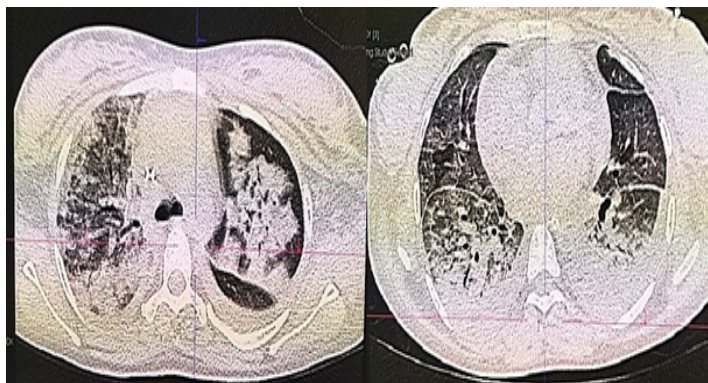
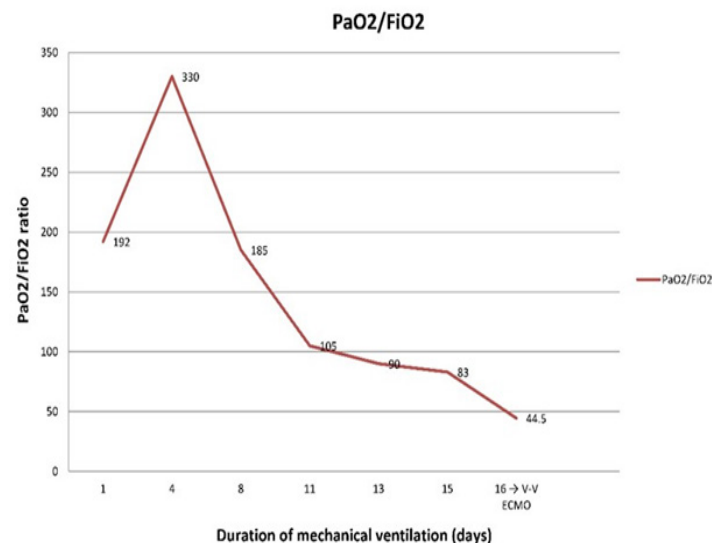


Figure 2: CT scan of the lungs of the patient B., 22 y.o. Severe ARDS.

The uterus was extirpated due to an increase in the infectious systemic inflammatory reaction (purulent-necrotic metroendometritis with signs of thrombophlebitis) at 12 days after an emergency caesarean section. Further, severe hypoxemia due to severe ARDS was persisted. Antibiotic therapy, SLE therapy, and endoscopic administration of surfactant (Surfactant-BL endobronchially 150 mg twice) were performed.

Despite the ongoing therapy, we observed normalization of procalcitonin levels, decrease in body temperature to subfebrile, but increasing restrictive parameters of mechanical ventilation and oxygen requirement (P_aO_2/FiO_2 - 44.5), also - negative X-ray dynamics, increasing in the volume of infiltration to subtotal (see graph 1).



Graph 1: Dynamics of the respiratory index. Development of severe ARDS in the patient B., 22 y.o.

An implantation of a veno-venous extracorporeal membrane oxygenation (VV-ECMO) system was performed, and we started protective lung ventilation. The surfactant was re-introduced endoscopically. The total duration of VV-ECMO therapy was 20 days. In the control chest CT, there

was positive dynamics - decreasing volume of consolidation in both lungs (P_aO_2/FiO_2 more than 300). The patient's recovery was complicated by development recurrence convulsive syndrome due to sedation stopped. Anticonvulsant therapy with valproate was started with positive effect. Plasma concentration of valproic acid was reached 63.10 $\mu\text{g/ml}$. Mechanical ventilation was continued 46 days.

Critical polyneuropathy was diagnosed. After 50 days of treatment in the intensive care unit (ICU), she was transferred to the therapeutic unit. Rehabilitation period was continued 1 month after ICU in hospital. The total duration of hospitalization was 119 days, in ICU - 63 days. After 6 months, the state of health is satisfactory. The child develops according to age. Consent was obtained from the patient to publish this report (April-August 2019).

SLE predominantly affects women during their reproductive years, occurring in about 1/1000 women aged between 15 and 45 years [1]. Pregnancy and the postpartum period provoke an exacerbation of SLE [3], which requires aggressive cytostatic therapy that can cause life-threatening conditions for the fetus and complications for the mother [4], one of which is PRES [5], phased diagnosis and timely treatment. Pregnancy can aggravate SLE, induce active stage of systemic lupus erythematosus, increase the incidence of complications and adverse outcomes, and pose a great threat to maternal and fetal health [1], as demonstrated by our clinical case. Although rare among SLE patients, PRES tends to be associated with high mortality rates and mainly concerns female gender [2]. The diagnosis is mainly radiological, CT may visualize hypodense lesions, but MRI remains the gold standard for diagnosis.

The pathophysiology of PRES in SLED is not yet completely explained [3]. However, there is theory of the reflex hypoperfusion of the brain secondary to endothelial dysfunction and exacerbated by vasoconstriction, spasm and/or autoimmune activation, therefore resulting in vascular hyperpermeability and vasogenic edema [4]. Extracorporeal life support, in particular VV-ECMO, was used by us as a backup therapy in a patient with severe ARDS. The Eolia study (2018) failed to rigorously demonstrate an improvement in 60-day mortality in severe ARDS [5]. However, the results of our use of VV-ECMO showed improvement in life-threatening hypoxemia, respiratory acidosis.

The mechanism that triggers the development of respiratory distress syndrome is the embolization of small vessels of the lungs with blood microclots, particles of damaged tissues against the background of toxic biologically active substances formed in the tissues - prostaglandins, kinins and others [6]. Violation of gas exchange is the result of an increase in the amount of interstitial water in the lung tissue [7]. Hypoxemia reflects the volume of intrapulmonary shunting, which is observed against the background of filling the alveoli with fluid, is accompanied by a significant decrease in lung elasticity, and the inspiratory reserve volume decreases. Filling the alveoli with fluid leads to the destruction of the surfactant, and, as a result, to multiple atelectasis. Decreased lung compliance is the result of interstitial and alveolar edema, fibrosis, and

Annals of Clinical and Medical Case Reports

surfactant deficiency [8]. It is possible that the use of surfactant in this patient also contributed to the successful treatment of severe ARDS. In our opinion, the success of patient' recovery is due to the continuity of the stages of treatment in multidisciplinary hospital, the coherence of the work of a multidisciplinary team, and the use of modern high-tech methods of diagnosis and treatment.

Acknowledgements relating to this article.

We thank the teams of intensive care units, departments of neurosurgery, obstetrics and gynecology, radiology, whose employees were directly involved in the diagnostics and treatment of the patient, and specialized specialists. We thank the staff of the Department of Anesthesiology and Resuscitation of the Institute of Medical Education of the Almazov National Medical Research Centre for their advisory assistance in the supervision of the patient. We thank the center management for support and participation in the fate of the patient at all stages of treatment.

References:

1. Buyon JP, Kim MY, Guerra MM, Lu S, Reeves E, Petri M, et al. Kidney Outcomes and Risk Factors for Nephritis (Flare/De Novo) in a Multiethnic Cohort of Pregnant Patients with Lupus. *Clin J Am Soc Nephrol CJASN*. 2017 Jun 7;12(6):940–6.
2. Mikdashi J, Nived O. Measuring disease activity in adults with systemic lupus erythematosus: the challenges of administrative burden and responsiveness to patient concerns in clinical research. *Arthritis Res Ther*. 2015 Jul 20;17:183.
3. Afilal I, Nasri S, Bendaoud M, Mahjouba H, Guerrouj I, Aidid F, et al. Fatal outcome of posterior reversible encephalopathy syndrome (PRES) in a lupus nephropathy patient: A case report. *Radiol Case Rep*. 2022 Jun;17(6):2215–9.
4. Hartman EN, Tuna K, Monsour E, Komanduri K, Tarasiuk-Rusek A. Seizure as an Initial Presentation for Posterior Reversible Encephalopathy Syndrome in Undiagnosed Systemic Lupus Erythematosus and Lupus Nephritis: A Case Report. *Cureus*. 2020 Sep 2;12(9):e10195.
5. Sameed M, Meng Z, Marciniak ET. EOLIA trial: the future of extracorporeal membrane oxygenation in acute respiratory distress syndrome therapy? *Breathe*. 2019 Sep 1;15(3):244–6.
6. Bos LDJ, Laffey JG, Ware LB, Heijnen NFL, Sinha P, Patel B, et al. Towards a biological definition of ARDS: are treatable traits the solution? *Intensive Care Med Exp*. 2022 Mar 11;10(1):8.
7. Ball L, Silva PL, Giacobbe DR, Bassetti M, Zubieta-Calleja GR, Rocco PRM, et al. Understanding the pathophysiology of typical acute respiratory distress syndrome and severe COVID-19. *Expert Rev Respir Med*. 2022 Apr;16(4):437–46.
8. Pérez-Gil J. A recipe for a good clinical pulmonary surfactant. *Biomed J*. 2022 Mar 7;S2319-4170(22)00030-0.