

## Bronchial Artery Embolization as a Life Saving Procedure - An Interesting Case Report

Salu FF<sup>1</sup>, Kumar K<sup>1\*</sup>, Raiya S<sup>1</sup> and Singh DK<sup>2</sup>

<sup>1</sup>Department of Radiodiagnosis, School of Medical Sciences and Research, Sharda hospital, India

<sup>2</sup>Department of Chest N Pulmonary Medicine, Sharda hospital, India

### \*Corresponding author:

Khemendra Kumar,  
Department of Radiodiagnosis, School of Medical  
Sciences and Research, Sharda hospital, India,  
E-mail: amicol91@gmail.com

Received: 21 Sep 2022

Accepted: 01 Oct 2022

Published: 07 Oct 2022

J Short Name: ACMCR

### Copyright:

©2022 Kumar K. This is an open access article distributed under the terms of the Creative Commons Attribution License, which permits unrestricted use, distribution, and build upon your work non-commercially

### Citation:

Kumar K, Bronchial Artery Embolization as a Life Saving Procedure - An Interesting Case Report. Ann Clin Med Case Rep. 2022; V10(1): 1-4

### Keywords:

Bronchial; Orthopic; Embolization

## 1. Abstract

Haemoptysis is a fairly common condition which is encountered in an emergency setting. However, the exact cause may not be easily identifiable. In such scenarios, bronchial artery embolization can be considered to stop the bleeding. This can be performed after a detailed pre-procedure CT thoracic angiography, which would help in identifying the source of the bleeding (bronchial/pulmonary) as well as delineate any anatomic variations of the bronchial artery origin. Knowing the anatomy of the bronchial artery origin, both orthopic and ectopic, help in shorter procedure time, hence less contrast and radiation exposure. Here, we present an interesting case of bronchial artery embolization.

## 2. Introduction

Bronchial artery embolization is a fitting minimally invasive procedure in an emergency setting when the aetiology of the haemorrhage isn't identified. It, hence, serves as a bridge to a more definitive intervention for haemoptysis [1].

Bronchial artery embolization offers success rate of 77-94% in an emergency setting since its introduction as early as 1973 [2]. However, it is vital to identify the origin of the bronchial artery that is to be embolized, for the procedure to be effective. Orthotopic origin from the proximal descending thoracic aorta is found in a vast majority. However, there can be ectopic origin in a small subset of this population, which would make the procedure that much challenging [3]. Contrast-enhanced computer tomography helps in identifying the origin Irrespective of whether it is orthotopic

or ectopic in nature. CECT, therefore, aids in treatment planning, shorted procedure time and reduced radiation exposure [4].

## 3. Case History

A 59-year-old male came presented with complaints of recurrent hemoptysis on and off for 1 year. Last bout of hemoptysis for massive in nature. Patient had the history of anti-tubercular treatment for pulmonary tuberculosis 1 year back. On examination he was found to be anemic (Hemoglobin-9gm/dl) and despite medical management there was persistent hemoptysis. Laboratory parameters revealed normal total leucocyte count, platelet count, PT INR, and APPT. CT thoracic angiogram was done localize the bleed and asses the bronchial artery anatomy for treatment planning. CT angiography revealed hypertrophied and tortuous, anomalous right bronchial artery from the right subclavian artery (Figure 1A). Left bronchial artery was orthotopic in origin and was not hypertrophied or tortuous. Fibro-atelectatic and fibro-bronchieatatic changes were in right upper lobe (Figure 1B). No active contrast blush was noted. Patient was taken for the bronchial artery embolization via right transfemoral arterial route. Despite multiple attempts bronchial artery was not cannulated due to the tortuosity of the aorta. It was decided to perform embolization via right trans brachial approach. The anomalous right bronchial artery was cannulated and embolization by 300–500-micron Poly Vinyl Alcohol (PVA) particle was done. Post procedure, patient was stable and no fresh complaints of hemoptysis. At 1 year follow up, no fresh complaints of hemoptysis were there.

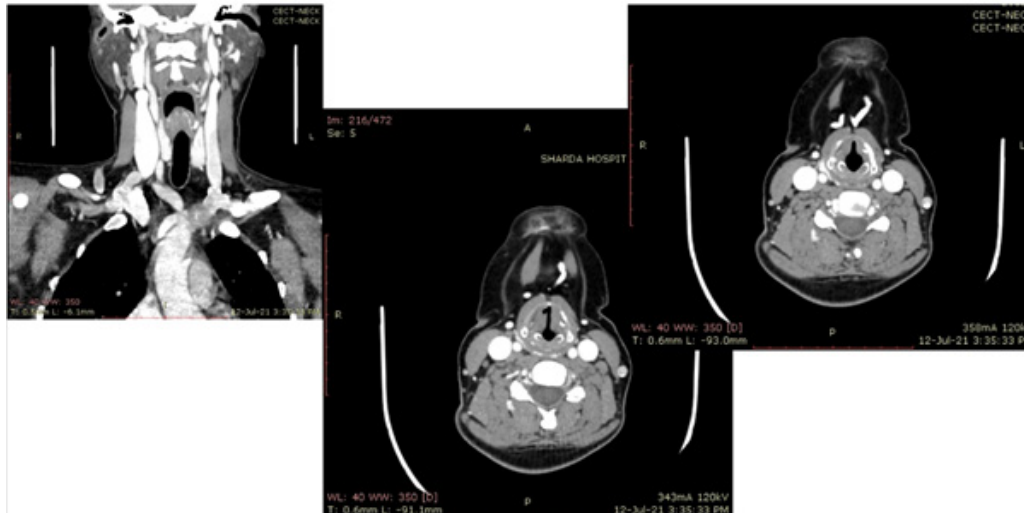


Figure 1:

#### 4. Discussion

The lung parenchyma has a dual vascular supply—pulmonary arteries and bronchial arteries. The pulmonary arteries are responsible for almost 99% of the blood flow to the lungs, and are necessary for alveolar gas exchange [5]. The bronchial arteries carry oxygenated blood to the lung parenchyma at a pressure close to systematic pressure, which is much higher than the pulmonary arteries. Hence, it can provide nourishment to the supporting lung structures [6]. The bronchial arteries traverse along these structures to the level of the respiratory bronchus, where their terminal branches achieve significant overlap with the pulmonary arterial circulation [1]. Angiographically, the orthotopic origin of bronchial arteries is noted to arise from the descending thoracic aorta between the upper T5 to the lower T6 vertebral bodies; seen in 70% of the population. On angiography, 1 cm above or below the level of the left main bronchus as the bronchial artery crosses the descending thoracic aorta is an important landmark [3]. Bronchial arteries that originate elsewhere in the aorta, but outside of the T5–T6 confines or from another vasculature are termed as ectopic [7-10]. Among ectopic origin, 10% of them are found to be the first order branch of the thoracic aorta or the arch. The remaining 20% originate from a variety of structures including brachiocephalic, subclavian, internal mammary, pericardiophrenic, or thyrocervical. They may also originate from abdominal aorta, inferior phrenic and celiac artery [11-13]. The four most prevalent patterns of bronchial artery branching at origin.

Type I: single right bronchial artery via intercostobronchial trunk (ICBT), and paired left bronchial arteries (41%).

Type II: single right bronchial artery via ICBT, and single left bronchial artery (21%).

Type III: paired right bronchial arteries with one from ICBT, and paired left bronchial arteries (20%).

Type IV: paired right bronchial arteries with one from ICBT, and solitary left bronchial artery (10%) (Figure 2) [11-13].

The normal caliber of the bronchial arteries is less than 1.5mm near the origin and less than 0.5mm distally, as they branch in the hilum. When hypertrophy occurs, its diameter usually exceeds 2 mm, and become tortuous in appearance [14]. Bronchial artery hypertrophy (BAH) and dilatation of the thin-walled distal bronchial to pulmonary artery anastomosis may occur. However, this recruitment increases the risk of bronchial artery rupture with subsequent pulmonary hemorrhage [5]. Bronchial arterial system is the main source of bleeding in 90% of the cases of massive hemoptysis, followed by the pulmonary arteries (5%), and the non-bronchial systemic arteries (5%) [15]. CECT angiography is preferred to be obtained from the supraclavicular regions upto the level of the renal arteries, depicting both orthotopic and ectopic bronchial arteries and possible collateral branches to the pulmonary arterial system. This is particularly helpful in cases of aberrant or ectopic bronchial arteries [16-18]. Digital subtraction arteriography is done prior to undergoing bronchial artery embolization. This allows for excellent delineation of both bronchial and non-bronchial systemic arteries [1]. Generally accepted guidelines for abnormal bronchial artery diameter are >3 mm, with normal vascular diameter typically 1.5 mm. Apart from this, pleural thickening measuring 3 mm or greater adjacent to a parenchymal abnormality is an important finding, when noted [19-21]. When a bleeding site cannot be identified, findings sensitive for localization of hemoptysis are vascular hypertrophy and tortuosity, neovascularity, hypervascularity, aneurysm formation, and shunting (bronchial artery to pulmonary vein or bronchial artery to pulmonary artery) [19]. Venous return from the bronchial arterial circulation is most often via the pulmonary veins, with smaller contributions from the superior vena cava, azygos, and hemiazygos systems. This venous system is well visualized during bronchial angiography and the interventionist must determine if direct arteriovenous shunting is present [1]. Embolization of the vessel was done by using PVA particles of size 300-350 microns. These PVA (Polyvinyl alcohol) particles do not undergo absorption and therefore theoretically provide a more

urable vascular occlusion. Small particles (< 200  $\mu\text{m}$ ) should be avoided because of the increased risk of spinal artery embolization compared with larger particles (> 300  $\mu\text{m}$ ) [8, 22]. After embolization of the aimed vascular territory to stasis or near stasis, a reduction in size and enhancement of the bronchial arteries are common findings. Bronchial artery embolization has proven to be effective in controlling the potential hazardous hemoptysis, with success rates between 73 and 100%.

Conclusion Bronchial artery embolization was introduced in 1974. It is now considered by many to be first line therapy [19]. Pre pro-

cedure contrast CT allows making timely diagnosis feasible in critically ill patients. In addition, bronchial and nonbronchial systemic feeder vessels can be detected. Awareness of anomalous bronchial arteries, especially in the absence of significant arterial supply to abnormal pulmonary parenchyma can be made during thoracic aortography. Pre procedural CT and Aortography helps in reducing the duration of procedure, thereby protects the patient from radiation exposure and excessive contrast administration. Anomalous origin of bronchial artery must kept in mind in patient with hemoptysis and should be differentiated from hypertrophied collaterals.

## On Expiratory Phase :

The brachiocephalic vein appears compressed between the sternum anteriorly , and the arch of aorta posteriorly.

Diameter: 2mm.

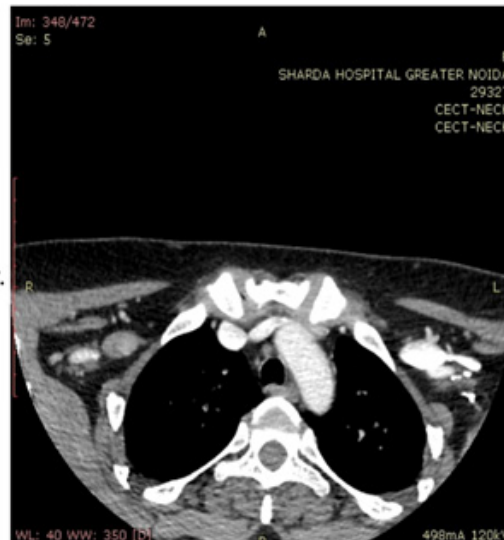

Figure 2:

## References

- Sopko D, Smith T. Bronchial Artery Embolization for Hemoptysis. *Seminars in Interventional Radiology*. 2011; 28(1): 48-62.
- Lopez J, Lee H. Bronchial Artery Embolization for Treatment of Life-Threatening Hemoptysis. *Seminars in Interventional Radiology*. 2006; 23(3): 223-9.
- Tanomkiat W, Tanisaro K. Radiographic relationship of the origin of the bronchial arteries to the left main bronchus. *J Thorac Imaging*. 2003; 18(1): 27-33.
- Almeida J, Leal C, Figueiredo L. Evaluation of the bronchial arteries: normal findings, hypertrophy and embolization in patients with hemoptysis. *Insights into Imaging*. 2020; 11(1).
- Bruzzi J, Rémy-Jardin M, Delhayé D, Teisseire A, Khalil C, Rémy J. Multi-Detector Row CT of Hemoptysis. *RadioGraphics*. 2006; 26(1): 3-22.
- Pump K. The Bronchial Arteries and Their Anastomoses in the Human Lung. *Diseases of the Chest*. 1963; 43(3): 245-55.
- Osiro S, Wear C, Hudson R, Ma X, Zurada A, Michalak M, Loukas M. A friend to the airways: a review of the emerging clinical importance of the bronchial arterial circulation. *Surgical and Radiologic Anatomy*. 2012; 34(9): 791-8.
- Hartmann I, Remy-Jardin M, Menchini L, Teisseire A, Khalil C, Remy J. Ectopic origin of bronchial arteries: assessment with multi-detector helical CT angiography. *European Radiology*. 2007; 17(8): 1943-53.
- Yoon W, Kim J, Kim Y, Chung T, Kang H. Bronchial and Nonbronchial Systemic Artery Embolization for Life-threatening Hemoptysis: A Comprehensive Review. *RadioGraphics*. 2002; 22(6): 1395-409.
- Remy-Jardin M, Bouaziz N, Dumont P, Brillet PY, Bruzzi J, Remy J. Bronchial and nonbronchial systemic arteries at multi-detector row CT angiography: comparison with conventional angiography. *Radiology*. 2004; 233(3): 741-9.
- Stoll J, Bettmann M. Bronchial artery embolization to control hemoptysis: A review. *Cardiovascular and Interventional Radiology*. 1988; 11(5): 263-9.
- Belcher J. Selective bronchial and intercostal arteriography. *British Journal of Diseases of the Chest*. 1971; 65: 253-4.
- Lord. The bronchial arteries: An anatomic study of 150 human cadavers. *American Heart Journal*. 1949; 37(3): 459.
- Osiro S, Wear C, Hudson R, Ma X, Zurada A, Michalak M, Loukas M. A friend to the airways: a review of the emerging clinical importance of the bronchial arterial circulation. *Surgical and Radiologic Anatomy*. 2012; 34(9): 791-798.
- Jean-Baptiste E. Clinical assessment and management of massive hemoptysis. *Critical Care Medicine*. 2000; 28(5): 1642-7.
- Remy-Jardin M, Bouaziz N, Dumont P, Brillet P, Bruzzi J, Remy J. Bronchial and Nonbronchial Systemic Arteries at Multi-Detector Row CT Angiography: Comparison with Conventional Angiography. *Radiology*. 2004; 233(3): 741-9.

17. Morita Y, Takase K, Ichikawa H, Yamada T, Sato A, Higano S, Takahashi S. Bronchial Artery Anatomy: Preoperative 3D Simulation with Multidetector CT. *Radiology*. 2010; 255(3): 934-43.
18. Furuse M, Saito K, Kunieda E, Aihara T, Touei H, Ohara T, Fukushima K. Bronchial arteries: CT demonstration with arteriographic correlation. *Radiology*. 162(2): 393-8.
19. Deffebach M, Lakshminarayan S, Kirk W, Butler J. Bronchial circulation and cyclooxygenase products in acute lung injury. *Journal of Applied Physiology*. 1987; 63(3): 1083-8.
20. Yoon W, Kim Y, Kim J, Kim Y, Park J, Kang H. Massive Hemoptysis: Prediction of Nonbronchial Systemic Arterial Supply with Chest CT. *Radiology*. 2003; 227(1): 232-238.
21. Yoon Y, Lee K, Jeong Y, Shin S, Chung M, Kwon O. Hemoptysis: Bronchial and Nonbronchial Systemic Arteries at 16-Detector Row CT. *Radiology*. 2005; 234(1): 292-298.
22. Burke C, Mauro M. Bronchial Artery Embolization. *Seminars in Interventional Radiology*. 2004; 21(1): 43-48.
23. Lee S, Chan JW, Chan SC, et al. Bronchial artery embolisation can be equally safe and effective in the management of chronic recurrent haemoptysis. *Hong Kong Med J*. 2008; 14(1): 14-20.
24. Katoh O, Kishikawa T, Yamada H, Matsumoto S, Kudo S. Recurrent Bleeding After Arterial Embolization in Patients with Hemoptysis. *Chest*. 1990; 97(3): 541-546.