

Heterotopic Pregnancy: Case Report

Flores AFM^{1*} and Neyra RR²

¹Department of Gynecology, Obstetrician Gynecologist, Gynecologist Oncologist, National Maternal Perinatal Institute, Lima, Peru

²Radiation Oncologist, Tumbes Regional Health Directorate, Tumbes, Peru

*Corresponding author:

Alan Francis Miranda Flores,
Department of Gynecology, Obstetrician Gynecologist, Gynecologist Oncologist, National Maternal Perinatal Institute, Jr. Miroquesada 941-Cercado de Lima, Peru, Tel: +51- 943683200;
E-mail: alanmiranda04@hotmail.com/
alanmiranda04@gmail.com

Received: 12 Aug 2022

Accepted: 18 Aug 2022

Published: 25 Aug 2022

J Short Name: ACMCR

Copyright:

©2022 Flores AFM. This is an open access article distributed under the terms of the Creative Commons Attribution License, which permits unrestricted use, distribution, and build upon your work non-commercially

Citation:

Flores AFM, Heterotopic Pregnancy: Case Report. Ann Clin Med Case Rep. 2022; V9(12): 1-4

Keywords:

Heterotopic pregnancy; Ectopic pregnancy; Laparoscopy

1. Abstract

Heterotopic pregnancy is defined by the presence of an intrauterine pregnancy and an ectopic pregnancy in any location, mostly in the uterine tubes. It is a rare obstetric pathology. However, in recent years its incidence has increased due to assisted reproduction treatments. His diagnosis remains a challenge. Ultrasound is the most important tool in its diagnosis and early identification. Laparoscopy remains the definitive method of extrauterine pregnancy. We present the case of a 39-year-old patient, with a gestation of 6 weeks by date of last menstrual period, with a diagnosis of heterotopic pregnancy, where the extrauterine pregnancy is located in the uterine tube.

2. Introduction

Heterotopic pregnancy is defined by the presence of an intrauterine pregnancy and an ectopic pregnancy in any location, mostly in the uterine tubes [1]. The first case was described by Duberney in 1708 in the findings of an autopsy in France [1-3].

This type of pregnancy is extremely rare, occurring in 1 in 30,000 to 50,000 spontaneous pregnancies. However, in recent years its incidence has increased due to assisted reproduction treatments, increasing by up to 1% in pregnancies achieved through these techniques [1, 2, 4, 5]. Others report an increased incidence of approximately 1 in 3,900 pregnancies achieved by infertility treatment [6].

The location of ectopic pregnancy is more frequent in the uterine tubes in up to 90% of cases, followed by the ovary (1-3%), cervix

(1%), interstitial (1%), abdominal (1%), and caesarean section scar (1-3%) [2].

In relation to the clinical picture, it can be asymptomatic in 24% of cases, abdominal pain in 72% and 54% have vaginal bleeding. In heterotopic pregnancy the chances of miscarriage are doubled [7, 8].

Early diagnosis is often extremely difficult because intrauterine pregnancy masks ectopic pregnancy [9]. Determination of human chorionic gonadotropin level and transvaginal ultrasound are the most useful options for diagnosis [1, 2, 6]. Early management is essential to avoid serious maternal complications, since it is associated with high maternal morbidity and mortality [1, 9]. The main objective in the treatment of this pathology is to terminate the extrauterine pregnancy without affecting the viable intrauterine pregnancy [2, 9-11].

Expectant management, ultrasound-guided local injection of hypertonic solutions, and laparoscopic surgery are options for the treatment of this disease. The best option will depend on the experience of the treating physician, as well as the clinical and hemodynamic status of the patient [1].

Fetal prognosis is mostly uncertain, even after treatment as approximately 35% of cases convert to spontaneous abortions [9].

3. Case Report

39-year-old patient, second pregnancy, no family history, no personal history, no surgical history, blood group O Rh +, non-reactive serological tests (HIV, RPR), with a 6-week pregnancy by date of

last menstrual period. It brings the result of a particular transvaginal ultrasound that concludes with a left tubal ectopic pregnancy of 6 weeks + 4 days and a human chorionic gonadotropin level of 23710 mU/mL. She goes to the emergency room due to slight vaginal bleeding 3 days ago associated with pelvic pain. On physical examination, he has blood pressure of 110/70 mmHg, heart rate of 88 beats per minute, respiratory rate of 16 per minute, temperature of 36.70. Abdominal examination showed no evidence of peritoneal signs. Vaginal examination revealed scant vaginal bleeding.

Laboratory tests reported a hemoglobin of 12.8 gr/dl, leukocytes of 10,900 cells/mm³, coagulation profile within normal parameters, glucose of 80 mg/dl, urea of 21 mg/dl, creatinine of 0.30 mg/dl, non-reactive Covid-19 antigen, negative urinalysis, human chorionic gonadotropin level of 25500mU/mL. A transvaginal ultrasound was performed that reported a uterus size of 90mm, endometrium of 7mm, a gestational sac of 13mm with the presence of an active embryo of 8mm in the left adnexa, free douglas cul-de-sac, concluding uncomplicated ectopic pregnancy. It was decided

to hospitalize the patient with the diagnosis of uncomplicated left adnexal ectopic pregnancy to the gynecology service for medical management and hemodynamic monitoring.

During hospitalization, a transvaginal ultrasound was performed in the infertility service, the findings being the presence of a gestational sac in the uterine cavity with an inactive embryo of 6mm by Crown-Rump Length (CRL). At the left paraovarian level, gestational sac is evident with an active embryo of 5mm by crown-rump length, heartbeats at 156 per minute, heterotopic pregnancy is concluded (Figure 1-3). It is decided to schedule for surgery.

A laparoscopic left salpingectomy was performed, the findings being the presence of a 3x2cm violaceous tumor in the left tube, at the level of the ampullary area. In addition, manual uterine aspiration was performed, with the findings being the extraction of uterine remains, regular quantity, without bad odor. The results of the pathologies confirm the presence of pregnancy.

The patient evolved favorably, her control hemoglobin was 12.2gr/dl. So she was discharged the next day.

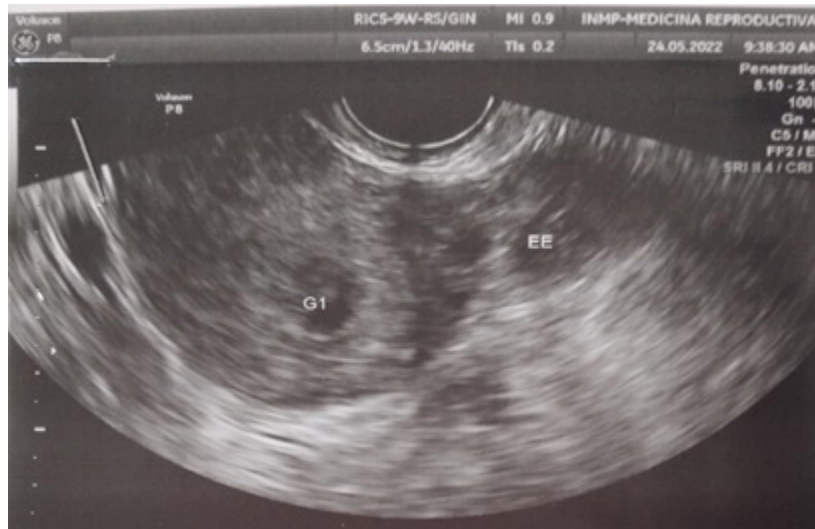

Figure 1: Ultrasound image of heterotopic pregnancy (G1: intrauterine pregnancy, EE: ectopic pregnancy).

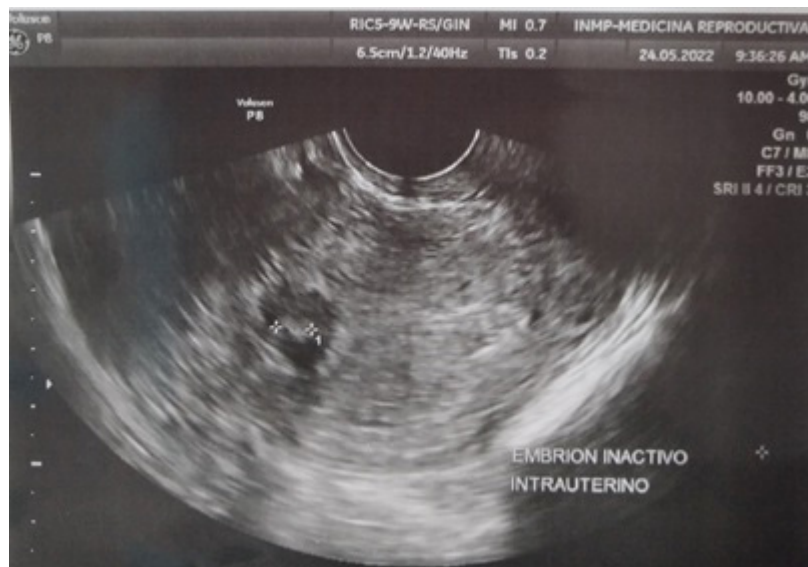

Figure 2: Intrauterine pregnancy with inactive embryo.

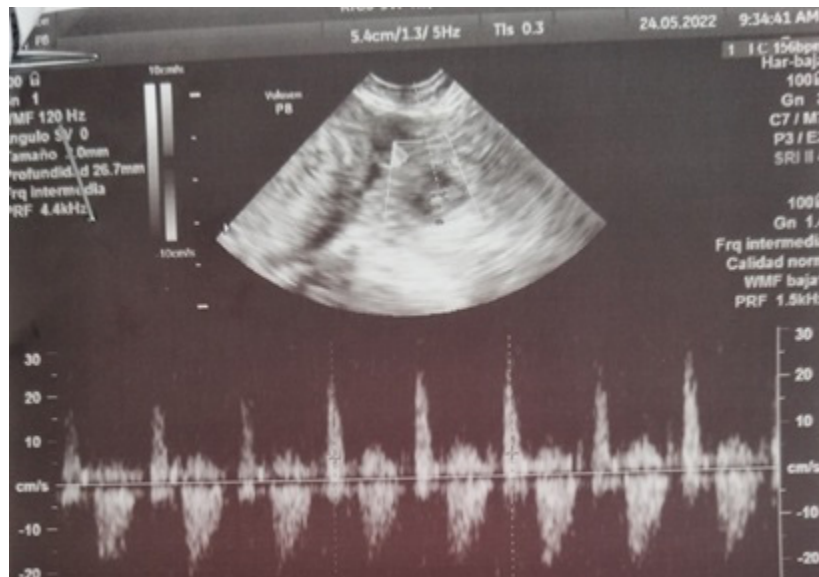


Figure 3: Active left tubal ectopic pregnancy.

4. Discussion

Heterotopic pregnancy is a rare obstetric pathology that can occur spontaneously or after the use of assisted reproductive techniques [3, 4, 7]. There are other risk factors for heterotopic pregnancy such as pelvic inflammatory disease, pelvic surgery, and damage or previous pathology of the fallopian tubes [3]. It has been reported that 50% of cases do not present identifiable risk factors [4]. Our case did not have any risk factors and conceived spontaneously, which is why it is more difficult to detect.

In 95% of cases, ectopic pregnancy occurs in the fallopian tube, but it can also be found in the cervix, cesarean section scar, ovary, interstitial segment and abdominal cavity.3 Ramírez et al.12 mentions a review by Reece that estimated that 94% of extrauterine pregnancies related to heterotopic were tubal and 6% ovarian. In our case, the ectopic pregnancy was located in the left uterine tube, confirming its high frequency in that area.

The clinical picture of heterotopic pregnancy varies widely, the most frequent being abdominal pain (80%), vaginal bleeding (50%) and hypovolemic shock (13%). It may be asymptomatic in 24% [1-3]. Therefore, early management is essential to avoid serious maternal complications, since it is associated with high morbidity and mortality [1, 9]. Oancea et al [9]. Carried out a systematic review on spontaneous heterotopic pregnancy where the majority presented abdominal pain as the main symptom. Yu et al [8] carried out a retrospective study in 25 cases, where 68% of the patients presented abdominal pain and/or vaginal bleeding and the remaining 32% were asymptomatic. Our case presented scant vaginal bleeding associated with pelvic pain.

Transvaginal ultrasound is a valuable tool in the diagnosis of heterotopic pregnancy combined with the measurement of human chorionic gonadotropin. There are no specific investigations available to detect this pathology, or even resort to exploratory laparoscopy or laparotomy in cases where the ultrasound findings are

not clear [9]. The detection rate in asymptomatic women is 15.8% and can vary from 41 to 84% in women with pelvic pain [10]. The most frequent ultrasound images are the adnexal mass and free fluid in the cul-de-sac of Douglas, in the presence of intrauterine pregnancy [13].

It is not easy to make the diagnosis when the embryo is not identified in the ectopic pregnancy [10]. The visualization of the embryonic cardiac activity of the ectopic pregnancy and of the intrauterine embryo constitute a pathognomonic sign of heterotopic pregnancy [10]. In patients with a known history of in vitro fertilization who are considered at high risk of presenting heterotopic pregnancy, their evaluation is carried out from early stages of pregnancy with ultrasound control, finding a reported sensitivity, specificity, positive predictive value and negative predictive value of 92 %, 100%, 100%, and 99%, respectively [4].

Early diagnosis of heterotopic pregnancy is often extremely difficult because an elevated serum human chorionic gonadotropin level and an intrauterine embryo seen on ultrasound suggest a normal pregnancy, and almost no one looks for a heterotopic pregnancy if the patient is asymptomatic [3]. In most cases, the diagnosis of heterotopic pregnancy is late, when rupture occurs and there is presence of hemoperitoneum [9].

About 70% of heterotopic pregnancies are diagnosed between 5-8 weeks of gestational age, 20% between 9 and 10 weeks, and 10% beyond 11 weeks [2-4, 10, 14]. Our case was diagnosed at 6 weeks of gestational age.

The treatment of heterotopic pregnancy will depend on the condition of the patient, the size and site of the extrauterine pregnancy, if she has had previous pregnancies, the viability of the intrauterine and extrauterine gestation, and the experience of the doctors [3]. The main objective is to terminate the extrauterine pregnancy without affecting the viable intrauterine pregnancy. Management includes several options from watchful waiting to ultrasound-guid-

ed local injection of potassium chloride or hyperosmolar glucose. The use of methotrexate is contraindicated in the presence of a live intrauterine pregnancy. Laparoscopy remains the definitive method of extrauterine pregnancy. Laparotomy has been reserved for patients with hemoperitoneum and hemodynamic instability [2, 10, 11, 13, 15].

The prognosis of intrauterine pregnancies is influenced by early management, with abortions reported in between 50% and 66% of cases. One in three will miscarry. 2.4 Survival rates of intrauterine gestation have increased from 35% to 54% in 1970, to about 70% today.4 Talbot et al [11]. mention a substantial improvement in the survival rate, between 48% and 51% in 1957; to 69% in 2007.

Yu et al [8]. carried out a retrospective study where most of the patients had successful perinatal results. 88% of the patients delivered live newborns without congenital anomalies, and three patients (12%) who underwent surgical treatment for removal of the ectopic pregnancy miscarried. Li et al [16]. Found an overall abortion rate of 14.8% in the group that was managed surgically [14].

5. Conclusion

Heterotopic pregnancy is a rare obstetric pathology, its diagnosis remains a challenge, it can occur spontaneously or after the use of assisted reproduction techniques, which has increased its incidence in recent years. Ultrasound is the most important tool in the diagnosis and early identification of heterotopic pregnancies. Laparoscopy remains the definitive method of extrauterine pregnancy.

References

1. Diaz N, Enriquez E. Tubal Heterotopic Pregnancy. Case Report. Case Reports. 2021; 7(2): 28-34.
2. Arrocha G, Espinoza J. Embarazo heterotópico y supervivencia del producto intrauterino. Reporte de un caso y revisión de la literatura. Revista Centroamericana Obstetricia y Ginecología. 2021; 25(1): 12-8.
3. Cerniauskaite M, Vaigauskaite B, Ramašauskaite D, Šilkunas M. Spontaneous Heterotopic Pregnancy: Case Report and Literature Review. Medicina. 2020; 56: 365.
4. Carrillo M, Rodríguez O. Embarazo heterotópico espontáneo con resultado perinatal favorable, reporte de un caso y revisión de la literatura. Revista Med. 2021; 29(1): 85-96.
5. Aracelis Villarreal Acosta. Embarazo heterotópico. Revista Cubana de Obstetricia y Ginecología. 2019; 45(1): 86-95.
6. Achmad K, Purnomo H, Riyan H, Budi W. Heterotopic Pregnancy: Diagnosis and Pitfall in Ultrasonography. Gynecology and Minimally Invasive Therapy. 2021; 10: 53-6.
7. Nabi U, Yousaf A, Ghaffar F, Sajid S, Mohamed H. Heterotopic Pregnancy - A Diagnostic Challenge. Six Case Reports and Literature Review. Cureus. 2019; 11(11): e6080.
8. Yu Y, Xu W, Xie Z, Huang Q, Li S. Management and outcome of 25 heterotopic pregnancies in Zhejiang, China. European Journal of Obstetrics & Gynecology and Reproductive Biology. 2014; 80: 157-61.
9. Oancea M, Ciortea R, Diculescu D, Poienar A, Grigore M, Lupean R, et al. Spontaneous Heterotopic Pregnancy with Unaffected Intrauterine Pregnancy: Systematic Review of Clinical Outcomes. Medicina. 2020; 56: 665.
10. Mendivil C, Padrón R, Miranda J, Silva G. Embarazo heterotópico: diagnóstico ecográfico temprano, manejo con laparoscopia. Reporte de un caso y revisión de la literatura. Revista Colombiana de Obstetricia y Ginecología. 2011; 62(1): 98-103.
11. Talbot K, Simpson R, Price N, Jackson S. Heterotopic pregnancy. Journal of Obstetrics and Gynaecology. 2011; 31(1): 7-12.
12. Ramírez J, Pimentel J, Cabrera S, Campos G, Zapata B. Embarazo heterotópico cervical: reporte de un caso. Revista Peruana de Ginecología y Obstetricia. 2015; 61(3): 301-6.
13. Monzón C, Tejada M, Oliva G. Embarazo heterotópico espontáneo. Presentación de dos casos. Revista Peruana de Ginecología y Obstetricia. 2019; 65(3): 355-9.
14. Ciebiera M, Słabuszewska J, Zaręba K, Jakiel G. Heterotopic pregnancy – how easily you can go wrong in diagnosing? A case study. Journal of Ultrasonography. 2018; 18: 355-8.
15. Gilberto Luna Lugo. Embarazo heterotópico espontáneo en pacientes con antecedente de embarazo gemelar familiar: 2 casos. Progresos de Obstetricia y Ginecología. 2012; 55(3): 141-5.
16. Li JB, Kong LZ, Yang JB, Niu G, Fan L, Huang JZ et al. Management of heterotopic pregnancy: Experience from 1 tertiary medical center. Medicine. 2016; 95: e2570.