

Annals of Clinical and Medical Case Reports

Case Report

ISSN 2639-8109 | Volume 9

A Case of Tendon Saving Stapedotomy with Postoperative Recovery of Acoustic Reflex

Hong JP, Kim SH, Kim MB and Chang SO*

Department of Otorhinolaryngology-Head and Neck Surgery, Kangbuk Samsung Hospital, Sungkyunkwan University School of Medicine, Seoul, Republic of Korea

*Corresponding author:

Sun O Chang,
Department of Otorhinolaryngology-Head and Neck Surgery, Kangbuk Samsung Hospital, Sungkyunkwan University School of Medicine, 29 Saemunan-ro, Jongno-gu, Seoul 03181, Republic of Korea,
Tel +82-2-2001-2269, Fax +82-2-2001-2273,
E-mail: suno.chang@samsung.com

Received: 07 Apr 2022

Accepted: 18 Apr 2022

Published: 23 Apr 2022

J Short Name: ACMCR

Copyright:

©2022 Chang SO. This is an open access article distributed under the terms of the Creative Commons Attribution License, which permits unrestricted use, distribution, and build upon your work non-commercially.

Citation:

Chang SO, A Case of Tendon Saving Stapedotomy with Postoperative Recovery of Acoustic Reflex. *Ann Clin Med Case Rep.* 2022; V9(1): 1-4

Keywords:

Stapes surgery; Stapedius tendon; Acoustic reflex

1. Abstract

Tendon saving stapedotomy is a delicate surgical technique which saves stapedius tendon while removing anterior and posterior crura of stapes. Preserving the incus-stapes tendon alignment during operation might give a chance to human's protective mechanism to recover acoustic reflex, which has a protective effect from barotrauma. Also, there are few more known benefits for tendon saving, such as improvement in noise filtering, stabilization of incus during prosthesis insertion and preservation of blood supply to distal incus. The authors present a case of 49-year-old female with bilateral otosclerosis, who received tendon saving stapedotomy in both ear. There was impaired acoustic reflex at early postoperative phase, but the reflex was recovered 1 year after surgery. With a review of literatures, authors report this case with a recommendation of tendon saving technique in stapedotomy.

2. Introduction

Acoustic reflex (stapedial reflex) is the human's defense mechanism against strong sound stimuli. Afferent auditory stimulation through the 8th cranial nerve is transmitted to the ventral cochlear nucleus and superior olivary nucleus of the brainstem, and it undergoes a process expressed by the efferent contraction of the stapedius muscle through the 7th cranial nerve on both sides. Acoustic reflex is one of the most sensitive tests to measure the mobility of stapes, and it disappears in an advanced case of otosclerosis. In general, the threshold of acoustic reflex increases in proportion to the degree of hearing loss, and in severe hearing loss, the acoustic reflex also disappears. The threshold of acoustic reflex is mostly formed between 70-100dB HL based on pure tone stimulation [1],

<http://www.acmcasereport.com/>

and the threshold is usually measured at four frequencies (500Hz, 1kHz, 2kHz, 4kHz). Stapedotomy is a procedure to resolve otosclerosis, and in most cases, it is performed either as an endaural approach or a transcanal approach under local anesthesia. The purpose of stapedotomy is to obtain mobility of the ossicles by placing an appropriate length of piston wire between the incus and the stapes footplate after removing the fixed stapes. Before placing the piston wire, an opening is made near the posterior 1/2~1/3 of the stapes footplate and during this process, in most cases, the stapedius tendon is sacrificed to get a better visualization for stapes crus. However, it is not impossible to selectively remove the anterior and posterior stapes crus while preserving the stapedius tendon. The authors performed a stapedotomy while preserving the stapedius tendon in both ears of a single patient at 7-year intervals, and experienced recovery of the acoustic reflex after at least 6 months of operation. With a review of literature, the authors report this case with a recommendation of tendon saving stapedotomy.

3. Case Presentation

A 49-year-old female patient with no past medical history visited our clinic complaining of progressive bilateral hearing loss. In the pure tone audiometry (PTA), the air conduction (AC) and bone conduction (BC) threshold of right side was 43 dB and 18 dB, and the left side was 44 dB and 17 dB. Carhart notch was observed in both ears, where the threshold of BC increased at 2 kHz level and the air-bone gap (AB gap) decreased. Acoustic reflex was not measured in both ear (Figure 1). Under the suspicion of bilateral otosclerosis, exploratory tympanotomy under local anesthesia was first performed on the left ear. During the operation, fixation

of the stapes was confirmed, and stapedotomy was done. The authors preserved stapedius tendon, and finished the operation after the insertion of 4.7mm sized piston wire. The patient showed subjective hearing improvement during the operation. 3 months after the surgery, the patient received PTA and acoustic reflex measurement, and the AC threshold in the left ear improved to 28 dB with decreased AB gap to 10 dB, but the acoustic reflex was still not measured. Afterwards, the patient did not visit the outpatient clinic for personal reasons. 7 years later, the patient came to our outpatient clinic for progressively worsened hearing of the right ear. PTA showed 66dB of AC threshold in the right side with 41dB of AB gap. AC threshold in the left side was 33dB without AB gap, confirming the good outcome of previous tendon saving stapedotomy. On the acoustic reflex test, there was no response on the right side, but the acoustic reflex was measured on the left side

(Figure 2). There was no specific finding in the endoscopic exam and the temporal bone computed tomography(TBCT) showed bilateral spongiosis of fissula ante fenestrum (Figure 3). Under the local anesthesia, an endaural stapedotomy was performed, and the stapedius tendon was preserved in the same way as in the previous stapedotomy of the left ear (Figure 4). The authors inserted 4.5mm sized piston wire, and the patient showed subjective hearing improvement during the operation. 6 months after the surgery, PTA showed improvement of AC threshold to 31dB without AB gap, but there was no acoustic reflex measured in the right ear. However, the acoustic reflex was measured on both sides at 1 year after the operation, confirming the recovery of the acoustic reflex after the tendon saving stapedotomy (Figure 5). The patient has been followed up regularly at our outpatient clinic without any specific complications.

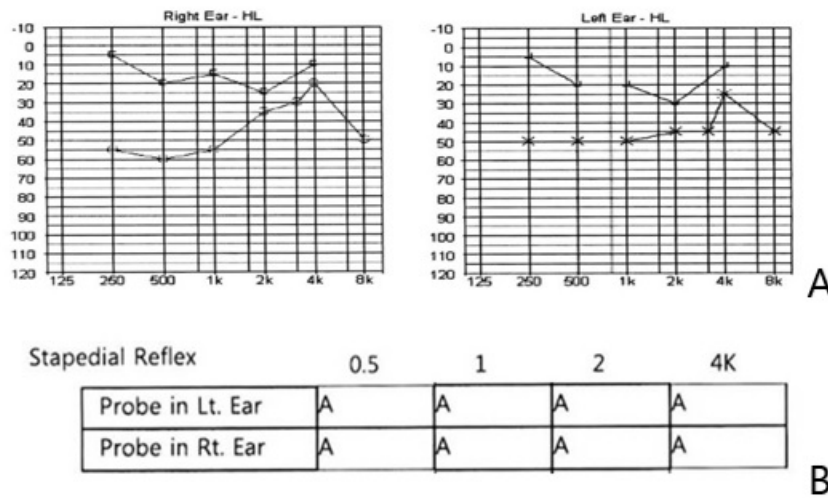


Figure 1: Primary PTA and Acoustic Reflex. “A” in the table means absence of reflex in the test. (A) Audiometry showed binaural conductive hearing loss with Carhart notch. (B) There was no acoustic reflex presented in both ear.

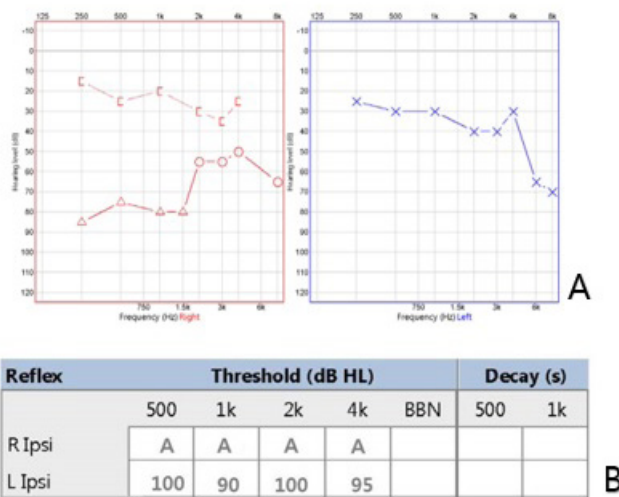


Figure 2: PTA and acoustic reflex after 7 years of follow up loss. (A) Hearing of operated ear(Lt) was well preserved. Hearing of non-operated ear(Rt) was exacerbated(from 43dB to 61dB) with increased air-bone conduction gap(from 25dB to 41dB) compared to previous audiometry(7 years ago). (B) “A” in the table means absence of reflex in the test. Unlike the Rt ear, Lt ear showed acoustic reflex. Considering that Lt ear didn’t showed acoustic reflex 3 months after previous operation, authors thought that remodeling of lenticular process-stapes head-tendon alignment may take time to be in a straight line.

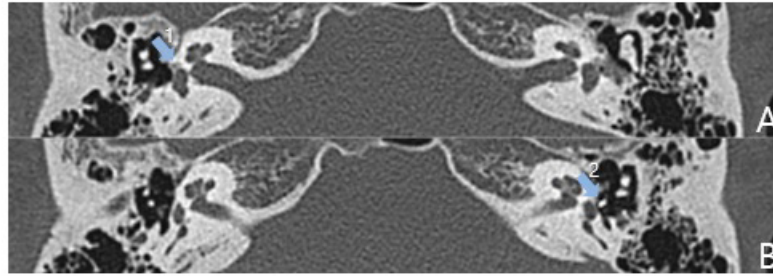


Figure 3: Preoperative(Rt) CT scan finding. (A) Preoperative CT scan showed lucent change of fissula ante fenestram(blue arrow 1) in Rt ear. (B) Previously inserted piston wire in Lt ear(blue arrow 2) was well in situ.

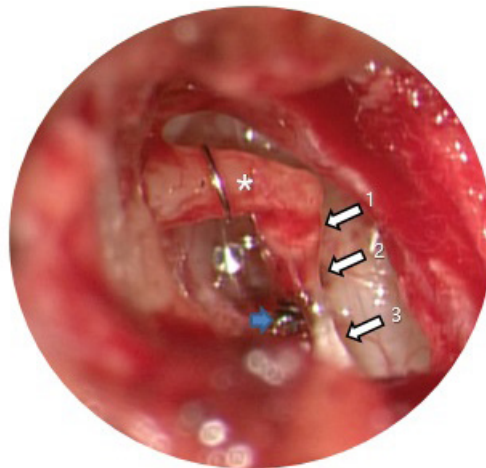


Figure 4: Intraoperative finding(Rt). The authors saved stapes head (arrow 1)-stapedius tendon (arrow 2)-pyramidal eminence (arrow 3) alignment intraoperatively. The 4.5mm piston wire was placed in long process of incus (astrix). During the operation, anterior crura of stapes was scissored cut and posterior crura of stapes was evaporated (blue arrow) by KTP laser.

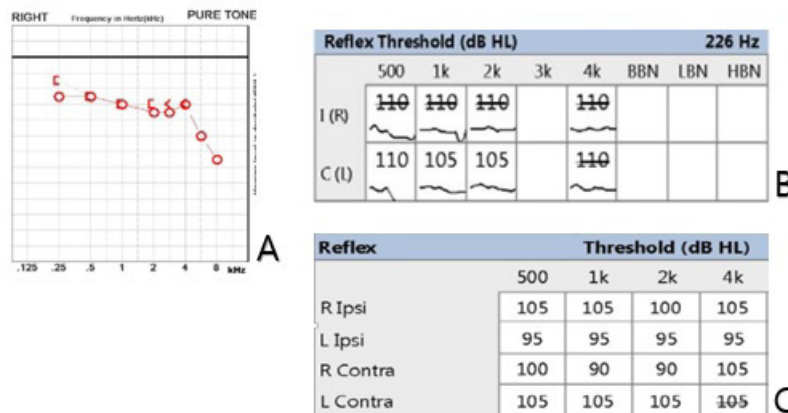


Figure 5: Postoperative(Rt) PTA and Acoustic Reflex. (A) Postoperative audiometry showed much improvement of hearing without remnant air-bone conduction gap in Rt ear. (B) “110” in the table means absence of acoustic reflex in the test. Acoustic reflex in the right ear was not measured 6 months after operation. The authors thought that biological remodeling of alignment was still in progress. (C) 1 year after operation, acoustic reflex of Rt ear was finally recovered. The authors confirmed that preserving stapedius tendon in stapedotomy showed restoration of acoustic reflex in both ear. The required period for recovery is thought to be at least 6 months.

4. Discussion

The middle ear converts sound energy from the external ear into physical vibration energy, and transmits it to the inner ear. Contraction of stapedius tendon stiffens the ossicular chain, and effects the masking of low frequency hearing (lower than 1~2kHz) [2]. The stapedius muscle, which located inside the pyramidal emi-

nence, is connected to the stapes neck through the stapedius tendon, and the contraction of the stapedius muscle is transmitted to the ossicles through delicate anatomical alignment. Acoustically, contraction of the stapedius muscle increases hearing ability in the noise setting, and also has the effect of protecting the inner ear from strong sound stimuli. The protective action of the stapedius

muscle can be confirmed through acoustic reflexes, and it is evaluated by checking decreased elasticity of tympanic membrane due to the contraction of the stapedius muscle and the stiffness of the ossicle chain. In the past, stapes mobilization by Rosen (1952) or stapedectomy by Shea (1956) were tried to treat otosclerosis [3,4], and nowadays they are replaced by stapedotomy using microdrills or lasers. Since the 1980s, the necessity of saving the stapedius tendon during stapedotomy has been continuously discussed, but in the early days of 1980s, it was argued that the tendon saving stapedotomy was not recommended because of increased rate of reoperation and no beneficial effect in hearing after surgery [5]. However, according to subsequent literatures, the actual reoperation frequency were not differed by saving the stapedius tendon, and moreover, the hearing ability tended to be better in a noisy environment regardless of the hearing gain. Also in terms of preserving the physiological structure of the human nature anatomy, tendon saving stapedotomy seemed to be more reasonable than sacrificing it [6-12]. In addition, there was opinion that saving tendon is advantageous because the physical stability of the incus is improved during the prosthesis replacement, and it is anatomically possible to maintain blood flow near the lenticular process [9]. The required period for the recovery of the acoustic reflex after preservation of the stapedius tendon is still unclear. In 1996, Causse reported at the American Otological Society Meeting that recovery of the acoustic reflex was observed after 1 year in 75% of patients who underwent stapedotomy and reconstruction of the stapedius tendon at the same time, but there was no further studies reported. In this case, the authors confirmed that the acoustic reflex did not recovered until 3 months after surgery in the left ear and 6 months after surgery in the right ear, and in the case of the right ear, it was confirmed that the acoustic reflex was recovered 1 year after surgery. So it was inferred that it would take at least 6 months to recover the acoustic reflex after preservation of the stapedius tendon. This can be understood as the period required for the structural alignment from the pyramidal eminence to the stapedius tendon, stapes neck, and lenticular process to have a contractile function for sound stimuli through biological remodeling. And also recovery itself means that the innate human defense mechanism is alive. The mere fact that the acoustic reflex can be recovered thought to be sufficient enough evidence for saving the stapedius tendon. According to what is known so far, the tendon saving stapedotomy does not increase the frequency of postoperative complications or the possibility of hearing loss, and considering the aspect of preserving the physiological structure of the human body, it should be actively attempted. However, due to technical difficulties, enough experience of the operator is required, and additional understanding of the benefits of the tendon saving stapedotomy is needed through future studies. Moreover, one should understand that recovery of the acoustic reflex may take several months after the operation.

5. Ethical Statement

This report was approved by the Institutional Review Board of the Kangbuk Samsung Hospital (IRB File No. 2022-01-031), and the requirement of informed consent was waived.

References

1. Moller A. Bilateral contraction of the tympanic muscles in man examined by measuring acoustic impedance-change. *The Annals of otology, rhinology, and laryngology*. 1961; 70: 735-52.
2. Moore BC. *An introduction to the psychology of hearing*: Brill. 2012.
3. Rosen S. Palpation of stapes for fixation: preliminary procedure to determine fenestration suitability in otosclerosis. *AMA archives of otolaryngology* 1952; 56: 610-5.
4. Shea Jr JJ. LXVIII fenestration of the oval window. *Annals of Otolology, Rhinology & Laryngology* 1958; 67: 932-51.
5. Karjalainen S, Häma R, Kärjä J. Results of stapes operations with preservation of the stapedius muscle tendon. *Acta oto-laryngologica* 1983; 96: 113-7.
6. Colletti V, Sittoni V, Fiorino FG. Stapedotomy with and without stapedius tendon preservation versus stapedectomy: long-term results. *The American journal of otology* 1988; 9:136-41.
7. Colletti V, Fiorino FG. Stapedotomy with stapedius tendon preservation: technique and long-term results. *Otolaryngology--Head and Neck Surgery* 1994; 111: 181-8.
8. Silverstein H, Hester TO, Rosenberg SI, Deems DA. Preservation of the stapedius tendon in laser stapes surgery. *The Laryngoscope* 1998; 108: 1453-8.
9. Silverstein H, Hester TO, Deems D, Rosenberg S, Crosby N. Outcomes after laser stapedotomy with and without preservation of the stapedius tendon. *Ear, nose & throat journal*. 1999; 78: 923-8.
10. Hazarika P, Mallick SA, Nayak DR, Pujary K, Balakrishnan R, Raj G. Results of KTP-532 laser and tendon preservation stapedotomy in otosclerosis-a preliminary report. *Indian Journal of Otolaryngology and Head and Neck Surgery* 2000; 52: 147-50.
11. Arnold A, Blaser B, Häusler R. Audiological long-term results following stapedotomy with stapedial tendon preservation. In: *Otosclerosis and Stapes Surgery*. (ed.: Karger Publishers;2007. p.210-4.)
12. Causse J-B, Vincent R, Michat M, Gherini S. Stapedius tendon reconstruction during stapedotomy: technique and results. *Ear, nose & throat journal*. 1997; 76: 256-69.