

## Management of Prolapsed End Transverse Colostomy: A Simple Local Revision

Wazir MUK, Almutawea A, Aljawder HS, Saeed MF\* and Juma IM

General surgery department, King Hamad University Hospital, Bahrain

### \*Corresponding author:

Mirza Faraz Saeed,  
General surgery department, King Hamad  
University Hospital, Bahrain,  
E-mail: dmirzafaraz@yahoo.co.uk

Received: 06 Mar 2022

Accepted: 15 Mar 2022

Published: 21 Mar 2022

J Short Name: ACMCR

### Copyright:

©2022 Saeed MF. This is an open access article distributed under the terms of the Creative Commons Attribution License, which permits unrestricted use, distribution, and build upon your work non-commercially.

### Citation:

Saeed MF, Management of Prolapsed End Transverse Colostomy: A Simple Local Revision. *Ann Clin Med Case Rep.* 2022; V8(16): 1-4

### Keywords:

Stoma; Stoma prolapse; Stoma revision; Stoma complication; colostomy

### 1. Abstract

Prolapsed colostomy is a well-known complication, occurring with transverse colostomies more frequently than other types of colostomies. It is usually managed conservatively when it is uncomplicated; however, surgical revision is advisable in complicated cases if the reversal of stoma cannot be done. We present a novel approach of local revision of transverse loop colostomy in a patient with synchronous splenic flexure and rectal adenocarcinomas, who was referred to our center after undergoing a Hartmann's procedure for splenic flexure tumor, and still pending surgical operation for rectal tumor. Here we describe a simple, reproducible procedure that does not involve entrance to the abdominal cavity, using readily available instruments in any secondary hospital. Post-operative follow-ups showed no recurrence, acute or chronic complications.

### 2. Introduction

Prolapsed stoma is a late complication (>3 months) of any ostomy formation, with a reported incidence varying between 7 and 26% [1,2]. Although prolapse can occur in any type of stoma creation, the highest rates reported are associated with loop transverse colostomy and end descending colostomies [1-4]. Numerous factors contribute to the high variability in incidence such as variations in the anatomical site (ileostomy, transverse, or sigmoid colostomy), whether it is a loop or end stoma, the etiology of the disease process (benign, malignant, inflammatory) and if it is an emergent or elective creation [1]. Prolapse is the telescoping of the intestine out from the stoma and becomes of hinderance for stoma appliance placement. If prolonged, it can lead to intestinal incarceration or strangulation due to the buildup of intestinal edema. Risk factors for prolapse include a large abdominal trephine, increased

intra-abdominal pressure, and a redundant loop of bowel proximal to the stoma [5]. Patients usually present because of the significant emotional and psychological distress caused by the prolapse [2]. Uncomplicated prolapse can be conservatively managed with manual reduction, local osmotic therapy with topical application of household sugar aids, which reduces edema and facilitates reduction of the prolapsed segment [6,7]. Complicated prolapse requires surgical intervention to potentially avoid strangulation and incarceration. We performed a local revision of a prolapsed by using readily available linear and circular staplers with the reconstruction of the stoma at its original site, avoiding the need for a laparotomy.

### 3. Case Presentation

A 58-year-old female presented to us in the clinic with a prolapsed stoma. She was known case of synchronous colorectal adenocarcinoma with two primary tumors located at the splenic flexure and the rectum. The patient underwent resection of the primary tumor at the splenic flexure and Hartmann's procedure with a transverse end colostomy that was followed by adjuvant chemo-radiation therapy for the rectal tumor in situ. For the past 6 months, the patient had developed a prolapse of the transverse end colostomy. The management was initially approached conservatively, with the use of a stoma belt and attempted manual reduction of the prolapse, albeit all conservative measures were unsuccessful. As there was no plan to resect her primary rectal tumor in situ and reverse the stoma, a local revision was preferred instead. The patient was planned for the local revision of the prolapsed stoma with a simple resection technique using linear and circular staplers as described in this case report with visual depictions of the technique preformed.

#### 4. Investigations

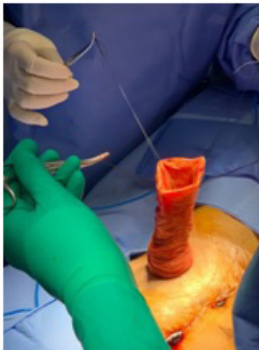
The patient was planned for surgery; pre-operative anesthesia clearance was obtained. The relevant preoperative labs done included Hemoglobin of around 14.1 g/dl with a creatinine level of 44.8 umol/L, normal electrolytes, and a Chest X- ray, which was also reported as normal.

#### 5. Differential Diagnosis

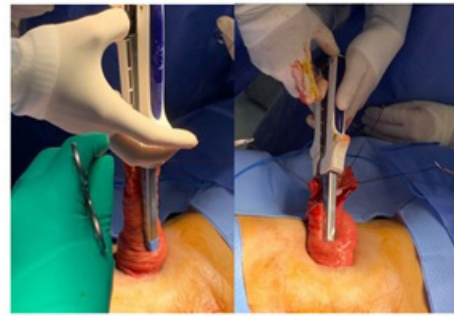
On examination in the clinic three weeks prior to surgery, we appreciated a fully functional prolapsed transverse colostomy that was pink in color. No ulceration, bleeding, or any parastomal hernias could be appreciated.

#### 6. Treatment/Management

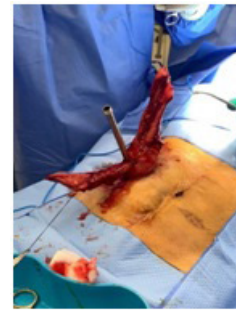The patient was admitted to the surgical ward the afternoon before the operation, started standard bowel preparation using 4 sachets of KLEAN prep, and 3 doses of oral Metronidazole 500 milligram every 8 hours, and was kept nil per oral for six hours prior to surgery. On the day of surgery, she had a morning chlorhexidine shower, pre-operative antibiotics were administered, and the prolapse segment was re-examined to correctly identify the transverse end colostomy. The patient underwent general anesthesia and was placed in the supine position. Four stay sutures with silk 3/0 were taken in all four quadrants and the prolapsed segment of the transverse colostomy was lifted vertically (Figure 1). A gastrointestinal linear purple stapler (GIA 100 mm; Covidien, Mansfield, MA, USA) was inserted into the lumen of the stoma and was used to transect the prolapsed stoma in a longitudinal fashion at the 3 O'clock position and then again at the 9 O'clock position (Figure 2). These two staple lines bisected the prolapsed segment into two halves (Figure 3). The two halves were then transected at the base in a perpendicular fashion with the use of ECHELON CONTOUR® curved cutter stapler (Figure 4). A total of four staple loads (two for the bisection and two for the transection of the base of each half) were used in the entire procedure. On final appearance, the prolapsed segment was completely removed, the circumferential margins of the stoma were reconstructed at its original site and fashioned as end transverse colostomy (Figure 5). After application of a stoma appliance the patient was awoken and taken to the recovery area. The operation time was 45 minutes in duration with no intra or post-operative complications reported.



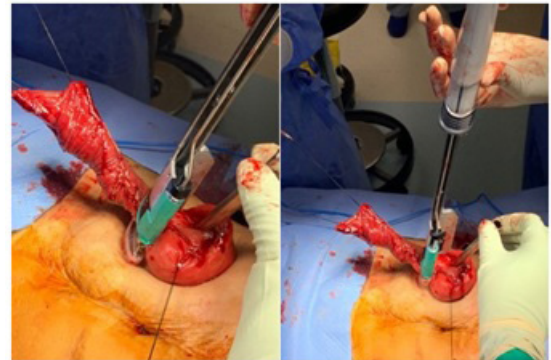
**Figure 1:** Sutures taken from four quadrants to lift the prolapsed segment



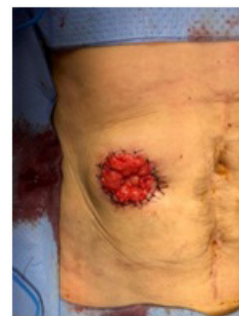**Figure 2:** GIA 100 Linear stapler was inserted into the lumen and transected the prolapsed stoma in a longitudinal fashion, at 3 O'clock and at 9 O'clock



**Figure 3:** The two staple lines bisected the prolapsed segment into two halves



**Figure 4:** The base of each half was transected using ECHELON Contour curved cutter stapler in a perpendicular fashion



**Figure 5:** The final appearance, stoma was reconstructed at its original site, and fashioned.

## 7. Outcome and Follow-up

The colostomy was patent, healthy, and functional after the surgery and the patient was discharged day 2 post-op without any complications. On follow up in the clinic both a week and a month later the stoma was functioning appropriately without any complications. The patient is following up with medical oncology for chemo-radiation therapy for her rectal tumour in situ.

## 8. Discussion

Stoma prolapse is one of the late complications of a stoma formation (>3 months). Of the late complications, stoma prolapse is one of the most common, with an incidence between 7 and 26 percent [1,2]. Stoma reversal is the best surgical option for addressing stoma prolapse. However, when reversal is not an option (as with our patient), alternative approaches including resection, revision, or relocation would be required [8]. Conservative interventions include application of ice or sugar, manually reducing the prolapsed section, or using a stoma belt can be used to delay time until stoma reversal is indicated. Stoma prolapse is very discomforting for patients and as consequence, the patient's quality of life is an indication for surgical repair, as was the case in our patient.

In this report we described a simple, safe, and effective approach to locally revise a transverse end colostomy. Local resection techniques are favourable in stomal prolapse that are not associated with parastomal hernia. With the use of readily available GIA staplers, we were able to successfully revise our patient's stoma and were satisfied with its final appearance [Figure 5]. This technique of locally revising a stomal prolapse is easily reproducible and we believe it must be part of any surgeon's armamentarium.

In comparison to abdominal approaches to stoma prolapse (laparotomy), local resection with a linear cutting stapler reduces morbidities associated with intra-abdominal entry, potential anastomoses, and re-operative surgery. It also reduces operative times with fewer steps in achieving a revised stomal prolapse when compared to an abdominal laparotomy approach [9-14]. The first of this case of local resection technique was reported in Italy in 2003, where a circular stapler was used to transect the prolapsed segment, no post-operative complications were reported [14]. Similarly, case reports from the United Kingdom, Japan and Greece who adopted the same linear cutting stapler resection techniques resulted in ideal outcomes [10-12]. Operative times ranged from twenty minutes [11] to fifty-nine minutes [13] using this technique.

Several of these case reports used local anesthesia [9-12] thus, further reducing complications associated with general anesthesia. In all reported cases thus far, no complications or recurrences were reported with similar local resection techniques as used in this case.

Furthermore, there is a lack of strong evidence on this technique and future prospective studies need to be undertaken. However, the technique is safe, effective, easily reproducible and has promising

outcomes with no recurrence or complications being reported.

## 9. Conclusion

This report highlights an easy-to-follow, step by step guide to a simple local approach in managing a stoma prolapse that could be easily reproduced. We believe surgeons who manage stomas should be accustomed with this low-cost, and highly effective local revision technique, especially when stoma reversal and laparotomy are not appropriate/indicated. In addition, having reviewed the data in this report we have deduced that this technique could be performed under local anesthesia, minimizing exposure of general anesthesia risks to the patient, and reducing the need for analgesia and antibiotics after surgery [9,10]. Having reviewed similar reported cases using this technique we have seen promising outcomes, in terms of satisfactory function and appearance. However, further studies are needed to assess the long-term outcomes of this local resection technique. Nonetheless, our report gives surgeons an alternative cheap, quick, and highly effective option in managing a prolapsed stoma in the short-term, with no recurrence and fully functional stoma.

## References

1. Arumugam PJ, Bevan L, Macdonald L, A J Watkins, A R Morgan, J Beynon, et al. A prospective audit of stomas--analysis of risk factors and complications and their management. *Colorectal Dis* 2003; 5: 49-52.
2. Robertson I, Leung E, Hughes D, M Spiers, L Donnelly, I Mackenzie, et al. Prospective analysis of stoma-related complications. *Colorectal Dis* 2005; 7: 279-85.
3. Harris DA, Egbeare D, Jones S, Benjamin H, Woodward A, Foster ME. Complications and mortality following stoma formation. *Ann R Coll Surg Engl* 2005; 87: 427-431.
4. Shellito PC. Complications of abdominal stoma surgery. *Dis Colon Rectum* 1998; 41:1562-72.
5. Shabbir J, Britton DC. Stoma complications: a literature overview. *Colorectal Dis* 2010; 12: 958-64.
6. Strong C, Hall J, Wilson G, Carney K. Common intestinal stoma complaints. *BMJ* 2021; 374: n2310.
7. Shapiro R, Chin EH, Steinhagen RM. Reduction of an incarcerated, prolapsed ileostomy with the assistance of sugar as a desiccant. *Tech Coloproctol* 2010; 14: 269-71.
8. Bafford AC, Irani JL. Management and complications of stomas. *Surgical Clinics*. 2013; 93(1): 145-166.
9. Masumori K, Maeda K, Koide Y, Hanai T, Sato H, Matsuoka H, et al. Simple Excision and closure of a distal limb of loop colostomy prolapse by stapler device. *Tech. Coloproctol*. 2012; 16: 143-145.
10. Ferguson H, Bhalerao S. Correction of end colostomy prolapse using a curved surgical stapler, performed under sedation. *Tech. Coloproctol*. 2010; 14: 165-167.
11. Tepetes K, Spyridakis M, Jatzitheofilou C. Local treatment of loop colostomy prolapse with a linear stapler. *Tech. Coloproctol*. 2005; 9: 156-158.

12. Hata F, Kitagawa S, Nishimori H. A novel, easy, and safe technique to repair a stoma prolapse using a surgical staple device. *Dig. Surg.* 2005; 22: 306-310.
13. Maeda K, Maruta M, Utsumi T. Local correction of a transverse loop colostomy prolapse by stapler device. *Tech. Coloproctol.* 2004; 8: 45-46.
14. Trentin G, De Simone P, Mainente P, Agresta F, Bedin N. Repair of mucosa stomal prolapse with circular stapler. *Chir. Ital.* 2003; 55(1): 141-143.