

## Herniation of the Ovary into the Canal of Nuck in a 3 Month Old Female Infant: A Rare Entity Needing Urgent Ultrasonography Evaluation

Kumar A\*, Ajmal R, Rehan R, Panhwar IA, Kumar A and Saleem E

Department of Radiology, Liaquat National hospital, Karachi, Pakistan

### \*Corresponding author:

Ashok Kumar,  
Department of Radiology, Liaquat National  
hospital, Karachi, Pakistan,  
E-mail: ashok.jeythwani@gmail.com

Received: 04 Mar 2022

Accepted: 15 Mar 2022

Published: 21 Mar 2022

J Short Name: ACMCR

### Copyright:

©2022 Kumar A. This is an open access article distributed under the terms of the Creative Commons Attribution License, which permits unrestricted use, distribution, and build upon your work non-commercially.

### Citation:

Kumar A, Herniation of the Ovary into the Canal of Nuck in a 3 Month Old Female Infant: A Rare Entity Needing Urgent Ultrasonography Evaluation. Ann Clin Med Case Rep. 2022; V8(15): 1-3

### Keywords:

Inguinal hernias; Canal of nuck; Canal of nuck hernias; Processus vaginalis; Labia majora swelling

## 1. Abstract

Indirect inguinal hernia of the canal of Nuck containing the pelvic organs such as ovary is a rare entity among females of pediatric age group which presents as swelling of labia majora. It is caused by congenitally failed closure of the processus vaginalis in female resulting in the formation of a potential space which is named as "canal of Nuck" through which pelvic organs herniate. Literature review showed that in female infants around 15-20% of the cases, this canal of Nuck hernia contains ovary with or without herniation of fallopian tube. Early diagnosis is important as there is a high chance of ovarian torsion as well as incarceration in such cases. Therefore, we present ultrasonographic appearances of indirect inguinal hernia of canal of Nuck containing ovary in 3-month old female infant who presented with complain of swelling of right labia majora since birth.

## 2. Introduction

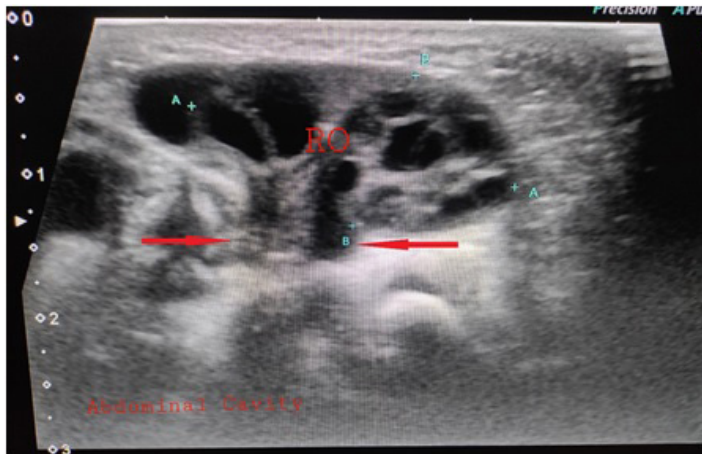
Hernia of inguinal canal in female of pediatric age group is an extremely rare condition [1, 2]. It occurs 6 times less commonly in females than males. The cause of this is failure of closure of the processus vaginalis, which forms a small protrusion of parietal peritoneum in females named as "canal of Nuck" measuring about 3 to 4 cms in size. The term Canal of Nuck was first described by Anton Nuck, a Dutch anatomist in 1691 [3,4,5]. It is a congenital entity in which the processus vaginalis remains patent in a female. This results in formation of potential space between the peritoneal cavity, inguinal canal reaching upto the labia majora [4] in male child his processus vaginalis accompanies with it the testis while

in female child it accompanies the round ligament which passes through the inguinal canal into the labia majora [2]. Usually the canal of Nuck obliterates almost at 8th month of gestation which starts from superior to inferior direction [3]. Failed obliteration of this canal results in herniation of abdomino-pelvic contents including abdominal fat, loops of bowel, abdominal fluid, part of urinary bladder and rarely ovary or uterus [3]. The patient may usually present with swelling of labia majora. Ultrasonography is noninvasive diagnostic investigation of choice for evaluation of this pathology [1,2]. Here we present ultrasonographic appearance of indirect inguinal hernia of canal of Nuck containing ovary in 3 month old female infant who presented with complain of swelling of labia majora since birth.

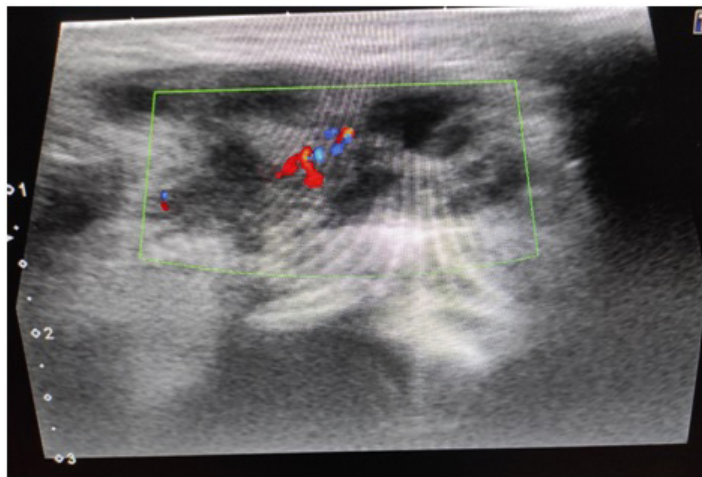
## 3. Case Report

A 3 month old baby girl presented to pediatric surgery OPD with complain of right labial majora swelling since birth which increase in size during crying. There was no history of fever. The baby was referred to Department of Radiology for ultrasonography of this swelling. Ultrasonography was performed by Linear High Frequency probe which revealed herniation of an ovoid solid structure through abdominal cavity into the inguinal canal of Nuck. It contained few tiny cysts predominantly along its peripherally. There was no evidence of peristalsis with in it. Findings were suggestive of herniation of right ovary through canal of Nuck. Color Doppler Examination was also performed which showed preserved vascularity within the ovary excluding the possibility of it strangulation or torsion. As the hernia was irreducible so the patient underwent

surgical exploration repair of right inguinal hernia. Operative findings confirmed the presence of viable right ovary within the hernial sac (Figure 1 and 2).



**Figure 1:** Longitudinal Grey Scale Ultrasonography image shows herniation of an ovoid solid structure through canal of Nuck (arrows) which contain few tiny cysts representing ovary.



**Figure 2:** Color Doppler image showing preserved vascularity within the ovary excluding the possibility of strangulation.

#### 4. Discussion

The current reported incidence of inguinal hernia in pediatric age groups almost ranges from 0.8% to 4.4% [1]. However, this hernia of the canal of Nuck is a rare entity in females of pediatric group [1,2,3]. It occurs when there is failure of obliteration of processus vaginalis in a female which usually obliterates at 8 month of gestation. If it remains patent then this result in formation of a potential space (canal of Nuck) through which abdomino-pelvic contents herniate [1-7].

A well-known risk factor for this condition is prematurity which has a reported incidence of inguinal hernias from 7% to 17% [3,7,8,9]. Risk of developing inguinal hernia persist until the age of 8 years in children who were born with very low birth weight [10]. Other risk factors include pulmonary disease, patients on mechanical ventilation, vigorous crying and long standing consti-

pation where herniation is results from persistently increased intra-abdominal pressure [3,7].

Patient may usually present with the complaints of swelling of Labia Majora with or without pain. Different structures can be herniated through canal of Nuck i.e. abdominal fat, segments of bowel loops, abdominal fluid, urinary bladder and rarely ovary or uterus. Around 15% to 20% of the cases, the canal of Nuck hernia contains ovary with or without the presence of fallopian tube [10]. One research showed that 10 out of 35 patients with surgically confirmed hernias of the canal of Nuck, hernia sac contained an ovoid solid mass with tiny cysts which was later confirmed by operative findings as an ovary. In 1 patient, the ovary was herniated together with uterus [1,2]. Herniation of the ovary through the canal of Nuck should be diagnosed as early as possible as there is a high risk of ovarian torsion as well as incarceration in these cases and has been reported in up to 43% of patients [5,6,8]. Therefore, prompt surgical intervention is necessary [3].

Ultrasound is the noninvasive diagnostic investigation of choice for evaluation of this pathology [8-11]. The presence of follicles may be helpful in diagnosing ovary in the hernia sac which may appear as peripherally arranged tiny clear cysts measuring 1 to 7 mm in size. The absence of peristalsis is another supportive finding in such cases [5]. Incarceration or torsion of ovary can be suspected when there is lack of blood flow on color Doppler ultrasound assessment [9]. Ultrasound examination should evaluate both inguinal regions as contralateral hernia can be found in 88% of cases without any clinical sign of swelling [9]. CT scan and MRI are more commonly used in complicated cases and also for diagnosis in adult population [1,2].

Many other differentials are described for a labia majora swelling in a female child such as hydrocele, Lymphadenopathy, Abscess, endometriosis as well as any benign or malignant neoplasm [1,2,4,8].

Surgical correction is required in almost all inguinal hernias in pediatric females while in adult population, surgical correction is only used when the patient is being symptomatic while conservative approach is used in asymptomatic patients [1,4,12].

#### 5. Conclusion

Hernia of the canal of Nuck is a very rare entity in females of pediatric age group. It should be diagnosed as early as possible. Because there is a high risk of ovarian torsion as well as incarceration in these cases which need immediate management. It can be diagnosed very easily by ultrasonography using linear high frequency probes. Therefore, very pediatric female patient presenting with labia majora swelling should be referred for sonologic evaluation to exclude the possibility of herniation of ovaries. Radiologists should also be familiar with the anatomy of canal of Nuck as well as sonologic appearances of contents of canal of Nuck hernia. The above case of ultrasonographic appearance of indirect inguinal

hernia of canal of Nuck containing ovary is a contribution in the literature for awareness of radiologists.

## References

1. Hamidi H, Rahimi M. Infantile presentation of the canal of Nuck hernia containing uterus and ovary: a case report. *Radiology Case Reports*. 2020; 15(12): 2557-9.
2. Jedrzejewski G, Osemlak P, Wieczorek AP, Nachulewicz P. Nuck canal hernias, typical and unusual ultrasound findings. *Ultrasound Quarterly*. 2019; 35(1): 79-81.
3. Kumar D, Maheshwari S, Rajesh U, Grewal D, Maria V. Herniation of the uterus, ovaries and fallopian tubes into the canal of Nuck in a 4-month-old child: A rare entity. *SA Journal of Radiology*. 2020; 24(1): 1-4.
4. Nasser H, King M, Rosenberg HK, Rosen A, Wilck E, Simpson WL. Anatomy and pathology of the canal of Nuck. *Clinical Imaging*. 2018; 51: 83-92.
5. Rekha KP, Abdullah S, Amin MB. Diagnosis of ovary-containing indirect inguinal hernia of the canal of Nuck by ultrasound. *Journal of Enam Medical College*. 2017; 7(1): 39-41.
6. Dal Mo Yang HC, Kim SW, Lim SJ, Park SJ, Lim JW. Ultrasonographic diagnosis of ovary-containing hernias of the canal of Nuck. *Ultrasonography*. 2014; 33(3): 178.
7. Kaya O, Esen K, Gulek B, Yilmaz C, Soker G, Onem O. The inguinal herniation of the ovary in the newborn: Ultrasound and color Doppler ultrasound findings. *Case Reports in Radiology*. 2014; 2014.
8. Muthiyal S, Kini V, Kounsai A, Ibrahim AA. Rarity in conspicuity—Ultrasound diagnosis of sliding left inguinal hernia through canal of Nuck with uterus, fallopian tubes and ovaries. *European journal of radiology open*. 2016; 3: 35-7.
9. Tamasi S, Minelli R, Giagnorio MG, Rossi E, Mamone R, Ferrara D, et al. Inguinal Hernia with Intestinal and Ovarian Content: A Rare Case in Pediatric Age. *Frontiers in Medical Case Reports*. 2020; 1: 1-06.
10. George EK, Oudesluys-Murphy AM, Madern GC, Cleyndert P, Blomjous JG. Inguinal hernias containing the uterus, fallopian tube, and ovary in premature female infants. *The Journal of pediatrics*. 2000; 136(5): 696-8.
11. Goske MJ, Emmens RW, Rabinowitz R. Inguinal ovaries in children demonstrated by high resolution real-time ultrasound. *Radiology*. 1984; 151(3): 635-6.
12. Clarke S. Pediatric inguinal hernia and hydrocele: an evidence-based review in the era of minimal access surgery. *Journal of laparoendoscopic & advanced surgical techniques*. 2010; 20(3): 305-9.