

Metastatic Adrenocortical Carcinoma Presenting as Intracavitary Mass in Right Atrium: A Case Report

Nawaz A*, Sadiq R and Zafar S

PINUM Cancer Hospital, Faisalabad, Pakistan

*Corresponding author:

Asrah Nawaz,
PINUM Cancer Hospital, Faisalabad, Pakistan,
E-mail: asrahnawaz@yahoo.com

Received: 02 Feb 2022

Accepted: 15 Feb 2022

Published: 19 Feb 2022

J Short Name: ACMCR

Copyright:

©2022 Nawaz A. This is an open access article distributed under the terms of the Creative Commons Attribution License, which permits unrestricted use, distribution, and build upon your work non-commercially.

Citation:

Nawaz A, Metastatic Adrenocortical Carcinoma Presenting as Intracavitary Mass in Right Atrium: A Case Report. *Ann Clin Med Case Rep.* 2022; V8(10): 1-4

Keywords:

Cardiac Myxoma; Metastatic Adrenocortical Carcinoma; Hypercortisolemia, Pulmonary Metastasis; Chemotherapy; Case Report

1. Abstract

1.1. Background: Adrenocortical carcinomas grow rapidly and tend to metastasize to liver and lungs and invade kidney, renal vein and Inferior vena cava (IVC). Cardiac metastases of the tumor is rare, less than 20 cases have been described and most of them occurred via direct extension through inferior vena cava into right atrium [1]. Endocardial Metastases from adrenocortical carcinoma presenting as an intracavitary growth in right atrium of heart without associated IVC involvement is very rare.

1.2. Case Presentation: We describe a case of 20 years old young male who presented to emergency with gradual worsening of dyspnea and facial swelling for last 6 months. Echocardiography showed a large Right atrial mass filling the whole chamber, attached to IAS (interatrial septum) via thin stalk suggestive of right atrial myxoma. Patient underwent resection of myxoma and histopathology proved it to be metastatic adrenocortical neoplasm. Whole body contrast enhanced CT scan showed primary large soft tissue mass lesion in right suprarenal location with metastatic bilateral lung metastases. On biochemical investigation associated hypercortisolemia was found.

1.3. Conclusion: Usually renal cell carcinomas spread intraluminally via inferior vena cava into the right atrium (reported in 1 % of tumors). Intracavitary presentation of metastatic adrenocortical carcinoma is very rare, and index case report was a similar presentation of a young male that underwent resection of intracavitary growth of right atrium (suspected as Myxoma), that came out to be metastatic adrenocortical carcinoma. In patients with advanced local or metastatic adrenocortical carcinomas, not amenable to sur-

gical resection, cytotoxic chemotherapy may be attempted.

2. Introduction

Adrenocortical Carcinomas (ACCs) are rare (incidence, 0.7-2 per million). ACC has bimodal age distribution, with peak incidence in early childhood and the fourth and fifth decade of life. Women are predominantly affected 55-60% [2, 3]. Most cases are sporadic, however ACCs have been observed in association with several hereditary syndromes. Approximately 60% of patients have adrenal hormone excess. Hyper secretion of cortisol called Cushing's syndrome, include weight gain, weakness, hypertension, hirsutism, central obesity, purple striae, supraclavicular fat pad, hyperglycemia and hypokalemia. Tumors can be aldosterone or androgen secreting. Harmonically inactive tumors produce symptoms related to tumor burden, including abdominal pain, back pain, early satiety and weight loss [2].

Being a highly malignant tumor, it grows rapidly and tends to metastasize to liver, lungs and tends to invade kidney, renal veins and inferior vena cava. Dissemination of the tumor occurs in 82% of patients with median survival to 14.5 months [4]. Cardiac involvement of adrenal carcinoma is very rare; less than 20 cases have been described and they have occurred via direct extension through inferior vena cava into right atrium [1]. The tumor may extend through the inferior vena cava into the right atrium or may present as solitary intracavitary growth in right atrium with no connection to IVC. First presentation of adrenocortical carcinoma as metastasis in suspected right atrial myxoma of heart is extremely rare and to the best of our knowledge has not been reported.

Metastasis to heart is generally a late manifestation of malignancy

as patient the patient usually has metastasis on other locations rarely, the heart is the only site of metastasis. According to the current standard of care, resection may be considered if greater than 90% of the tumor and metastases can be removed. Otherwise, systemic therapy should be initiated. For monometastatic or polymetastatic disease, local therapy may be considered (ie, RFA, RT) [5].

3. Case Repot

We describe a case of 20 years old young male, with no significant past history, who presented to emergency in September 2019 with gradual worsening of dyspnea and facial swelling for last 6 months. Echocardiography showed a large Right atrial mass filling the whole chamber and protruding through tricuspid valve into right ventricle. The mass was attached to IAS (interatrial septum) via thin stalk suggestive of right atrial myxoma. On the basis of provisional diagnosis of right atrial myxoma surgical resection of myxoma was done via open heart surgery.

Atrial Mass was measuring 7.5x4.9 cm. Cut surface showed a well circumscribed grey white nodular piece measuring 1.9cm and showed tan yellow patchy areas. Microscopic examination revealed a nodule of tumor along with fibrin thrombus showing nest of neoplastic cells having vesicular nuclei with inconspicuous nucleoli, coarse chromatin and moderate pale staining to eosinophilic cytoplasm. Mitotic figures were also noted. IHC was done and tumor cells were positive for CD56, synaptophysin and Melan A while negative for Cytokeratin AE1/AE3, EMA, Chromogranin,

S-100, HMB-45 and SALL-4. So it proved to be metastatic adrenocortical neoplasm.

On presentation to our Oncology department in November 2019, patient had facial swelling with associated flushing. Rest of the general physical examination was unremarkable. His whole body contrast enhanced CT scan was performed that showed primary large soft tissue mass lesion in right suprarenal location with metastatic bilateral lung metastases and mediastinal lymphadenopathy. No IVC thrombus or tumor extension was identified Figure 2. Biochemical workup showed associated hypercortisolemia (indicated by raised 24hr urinary cortisol levels). After being discussed in multidisciplinary tumor board, patient was planned for chemotherapy and he completed 6 cycles of cisplatin etoposide. Patient was switched to triplet regimen by adding doxorubicin to cisplatin etoposide after 6 cycles because Interim staging evaluation showed slight disease progression but biochemical and symptomatic improvement. Patient was put on hydrocortisone replacement. Patients' disease regressed after receiving 6 cycles of triplet regimen but surgical debulking was not possible. Patient had treatment free period of 11 months during which patient did not visit for follow-up.

Patient visited in December 2022 again with facial edema and hypercortisolemia. Patient had interval development of liver metastases and suprarenal mass progression. Now after multidisciplinary discussion patient is again started on chemotherapy cisplatin and etoposide.

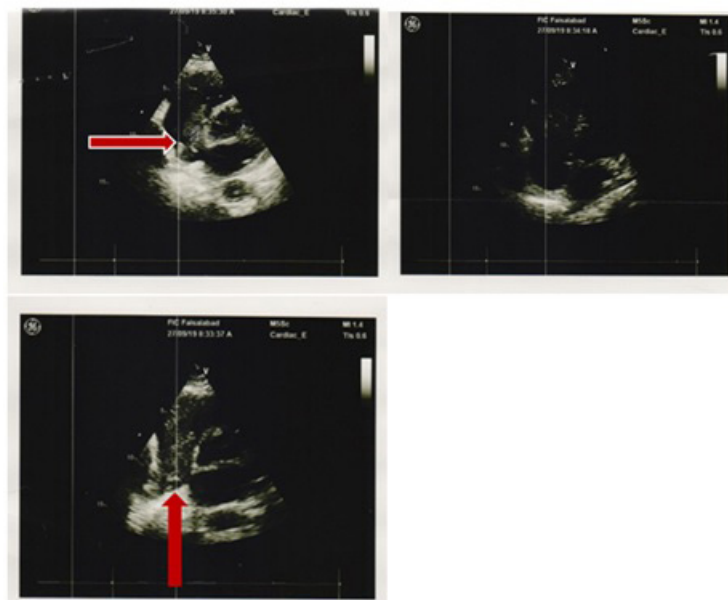
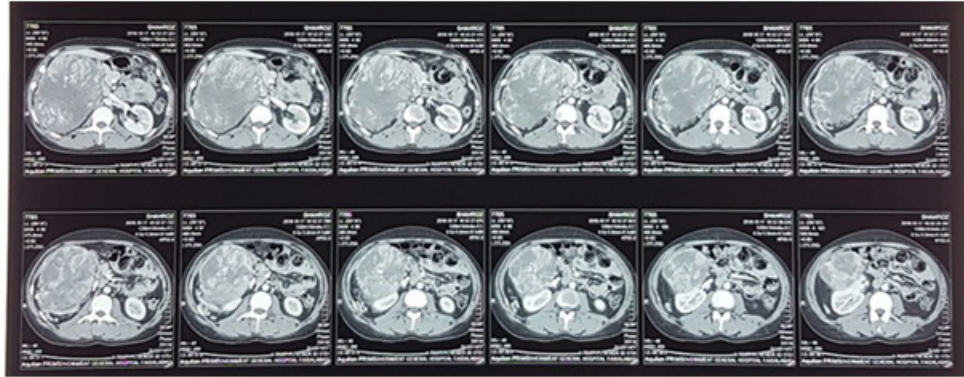


Figure 1: Preoperative echocardiography of patient showing right atrial mass (myxoma), indicated by arrow heads.

A.



B.

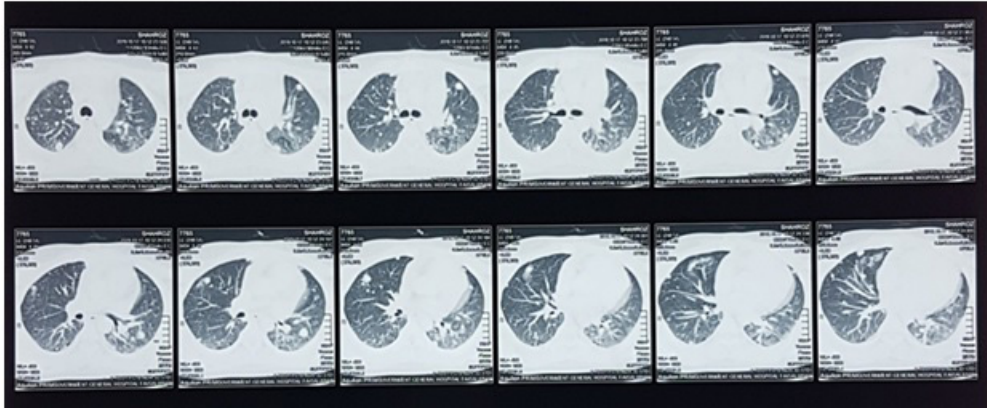


Figure 2: (A): CT manifestation of primary large soft tissue mass lesion in right suprarenal location 11x9cm) abutting segment 6 of liver (B): Metastatic bilateral lung nodules.

4. Discussion

Cardiac neoplasms are rare, mostly metastatic in origin. The reason being strong kneading action of myocardium, metabolic peculiarities of striated muscle, rapid blood flow through the heart and the fact that lymphatic flow is directed away from the heart [6]. Cardiac metastases are found at autopsy in 6-20% of patients with malignant neoplasms [7]. More than one third (36%) of cardiac metastases originate from lung cancer. Leukemia, lymphoma and Kaposi sarcoma account for 20% of cardiac metastases, breast carcinoma for 7% and esophageal carcinoma for 6% [8]. Cardiac metastases are the immediate cause of death in as many as one third of cases in which the do occur [9]. Usually, the symptoms are insidious in young and middle-aged patients

Symptoms may be specific, such as pericardial effusion with tamponade, arrhythmias, valvular dysfunction, intracardiac blood flow abnormalities, congestive cardiac failure, dyspnea, chest pain, syncope, hemoptysis and sudden cardiac death [10]. Metastatic cardiac tumors unlike benign cardiac tumors induce rapid changes in systemic symptoms that lead to poor outcomes [11]. Echocardiogram is helpful in detecting intracardiac lesions.

Metastases may reach heart via lymphatic or hematogenous route, or by direct or transvenous extension. Lymphatic spread tends to give rise to pericardial metastases, hematogenous spread preferentially gives rise to myocardial metastases. Only rarely are endocardial tumor deposits found. Carcinomas of breast and lung

<http://acmcaseports.com>

invade the epicardial and then myocardial lymphatic system of heart. Adrenocortical tumors usually spread to heart via inferior vena cava (1% of cases have been reported). Secondary heart tumors having partial or total intracavitary growth with infiltration of inter atrial septum are very rare and when they occur they are covered by thrombotic material. Involvement of cardiac chambers is usually due to tumor thrombosis and is through the vena cava or retrograde flow from the lymphatic channels [12]. The malignant cells attach to the cardiac endothelial surface and then proliferate. It is not clear why the right ventricle is the most common cardiac chamber that is affected as the metastatic site.

Because chemotherapy has limited value in the treatment of ACC, complete surgical resection is the treatment of choice if possible [13]. Our patient had metastatic ACC with RA and lung involvement which was not amenable to surgical resection, so chemotherapy was planned by multidisciplinary board.

Several cytotoxic agents has been used as single drug or in combination to treat advanced ACC including cisplatin, doxorubicin, etoposide, vincristine, and 5-fluorouracil (FU). We used cisplatin etoposide doublet 6 cycles followed by triplet by adding doxorubicin. Chemotherapy lead to biochemical and symptomatic improvement and ultimately better quality of life. Patient was put on hydrocortisone replacement. No grade 3 or 4 adverse effects occurred during treatment. Patient is still alive 27 months post diagnosis and is still receiving chemotherapy due to disease progression.

5. Conclusion

We suggest that adrenal carcinoma, although very rare, should be included in the differential diagnosis of right atrial tumors. Metastatic Thrombus formation in the right atrium by invasion is rare and surgical resection is the choice treatment for these cases, resulting in improved survival rates. Once an adrenal tumor is detected, the work-up should include echocardiography, which is of a paramount importance in the evaluation of cardiac involvement, operative planning if required. In patients with advanced local or metastatic disease, not amenable to surgical resection, cytotoxic chemotherapy may be attempted.

References

1. Rosen B, Rozenman Y, Harpaz D. Extension of adrenocortical carcinoma into right atrium, echocardiographic diagnosis: A Case Report. 2003; 1.
2. Fassnacht M, Dekkers O, Else T, Baudin E, Berruti A, de Krijger RR, et al. European Society of Endocrinology Clinical Practice Guidelines on the Management of Adrenocortical Carcinoma in Adults, in collaboration with the European Network for the Study of Adrenal Tumors. *Eur J Endocrinology*. 2018; 18-0608.
3. Fassnacht M, Kroiss M, Allolio B. Update in adrenocortical carcinoma. 2013; 98: 4551-64.
4. Luton JP, Cerdas S, Billaud L, Thomas G, Guilhaume B, Bertagna X, et al. Clinical Features of Adrenocortical Carcinoma, Prognostic Factors, and the Effect of Mitotane Therapy. *N Engl J Med*. 1990; 322: 1195-201.
5. National Comprehensive Cancer Network. NCCN guidelines. [Online] 2019.
6. Prichard RW. Tumors of the heart; review of the subject and report of 150 cases. *AMA Archives of Pathology*. 1951; 51: 98-128.
7. Pinho T, Rodrigues-Pereira P, Araújo V, Oliveira NP, Macedo F, Graça A, et al. Cardiac metastasis of melanoma as first manifestation of disease. 2009; 28.
8. Chiles C, Woodard PK, Gutierrez FR, Link KM. Metastatic involvement of the heart and pericardium: CT and MR imaging. *Radiographics*. 2001; 21.
9. Hallahan DE, Vogelzang NJ, Borow KM, Bostwick DG, Simon MA. Cardiac metastases from soft-tissue sarcomas. *Journal of Clinical Oncology*. 1986; 4.
10. Takenaka S, Hashimoto N, Araki N, Hamada K, Naka N, Joyama S, Kakunaga S, et al. Eleven cases of cardiac metastases from soft-tissue sarcomas. *Jpn J Clin onc*. 2011; 41: 514-8.
11. Togo A, Muramatsu T, Tsukada H, Ikeda M, Shida M, Hirasawa T, Maeda M. Case of metastatic uterine cervical squamous cell carcinoma in the right atrium. *The Tokai Journal of Experimental and Clinical Medicine*. 2013; 38: 42-5.
12. Hanfling SM. Metastatic cancer to the heart. Review of the literature and report of 127 cases. *Circulation*. 1960; 22: 474-83.
13. Allolio B, Hahner S, Weismann D, Fassnacht M. Management of adrenocortical carcinoma. *Clin Endocrinol (Oxf)*. 2004; 60: 273-87.
14. Locali RF, Matsuoka PK, Cherbo T, Gabriel EA, Buffolo E. *Arq Bras Cardiol*. 2009; 92: 168-76.