

Annals of Clinical and Medical Case Reports

Case Report

ISSN: 2639-8109 | Volume 8

Rare Bullous Pemphigoid During PD-1 Inhibitor Therapy: A Case Report

Zuopeng Xiao BS^{1,2}, Mengjun Nie BS^{1,2} and Xi Zou^{1*}

¹The Affiliated Hospital of Nanjing University of Chinese Medicine, Jiangsu Province Hospital of Chinese Medicine, Nanjing, Jiangsu 210029, China

²No.1 Clinical Medical College, Nanjing University of Chinese Medicine, Nanjing, Jiangsu 210023, P.R. China

*Corresponding author:

Xi Zou,
The Affiliated Hospital of Nanjing University of Chinese Medicine, Jiangsu Province Hospital of Chinese Medicine, 155 Hanzhong Road, Nanjing, Jiangsu 210029, P.R. China, Tel: 86-18051983568;
E-mail: zxvery@126.com

Received: 28 Jan 2022

Accepted: 07 Feb 2022

Published: 14 Feb 2022

J Short Name: ACMCR

Copyright:

©2022 Xi Zou. This is an open access article distributed under the terms of the Creative Commons Attribution License, which permits unrestricted use, distribution, and build upon your work non-commercially.

Keywords:

Case report; Immune checkpoint inhibitors; Bullous pemphigoid; Adverse skin reactions; Treatment

Abbreviations:

PD-1; Programmed Cell Death Protein 1, BP; Bullous Pemphigoid, MRI; Magnetic Resonance Imaging, IgG; Immunoglobulin G, IgM; Immunoglobulin M, IgA; Immunoglobulin A, C3; Complement Component 3, SJS; Stevens-Johnson Syndrome, AGEP; Acute Generalized Exanthematous Pustulosis, irAEs; Immune-Related Adverse Events

Citation:

Xi Zou, Rare Bullous Pemphigoid During PD-1 Inhibitor Therapy: A Case Report. 2022; V8(8): 1-4

1. Abstract

Immunotherapy is an important treatment modality in cancer, but it can also cause adverse reactions, with skin toxicity being the most common. The increasing number of immune checkpoint inhibitors being used in the clinic will inevitably cause an increase in the rate of adverse skin reactions that markedly affect the patient's quality of life. A 58-year-old patient with intrahepatic cholangiocarcinoma developed bullous pemphigoid (BP) nearly a year after using immune checkpoint inhibitors, which is different from what has been reported in the literature within two weeks of treatment. Pathologically, the skin biopsy diagnosis was epidermal hyperplasia and focal sub-epidermal pustule formation, consistent with drug-induced dermatitis. The patient was treated with methylprednisolone, minocycline, colchicine, nicotinamide, triamcinolone, and traditional Chinese medicine decoction. No new blisters developed after 1 week of treatment. The medication was gradually discontinued, and BP did not recur. Clinicians should carefully consider the risk-benefit ratio when using PD-1 inhibitors, particularly with respect to rash severity. Further studies are needed to investigate relationship between adverse skin reactions and drug efficacy.

2. Introduction

Immune checkpoint inhibitors, such as anti-programmed cell

death 1 (PD-1), can enhance the anti-tumor function of T cells and increase the activity of the immune system. However, normal tissues and organs can be affected by an overactive immune system, causing an immune-related adverse reaction [1,2]. Adverse skin reactions are the most common side effects of immune checkpoint inhibitor treatment. However, adverse skin reactions are completely atypical [3]. We report herein a case of uncommon features of adverse skin from immunotherapy treatment. The case is the first that we have experienced to present such features since using PD-1 inhibitor treatment.

3. Case presentation

In May 2017, the patient underwent right hepatectomy + cholecystectomy due to liver lesions found on physical examination. Postoperative pathology revealed intrahepatic cholangiocarcinoma, moderately differentiated tumor measuring 8×5×5 cm, blood vessel invasion, and no obvious nerve invasion. Tegafur (1.5 mg days 1-14) oral chemotherapy was administered for six cycles after surgery. Magnetic resonance imaging (MRI) on September 2019 showed liver lesions, and recurrence was considered. However, the patient was ineligible for surgery; as such, seven cycles of oxaliplatin (150 mg day 1) + gemcitabine (1 g day 1) chemotherapy combined with lenvatinib targeted therapy and with toripalimab (240 mg day 1) immunotherapy was initiated. After tumor

shrinkage was confirmed, the patient underwent hepatectomy on March 18, 2020, and a 1.5×1.1 cm mass was resected during the operation. Subsequently, the patient received six cycles of capecitabine (1.5 g bid) chemotherapy combined with lenvatinib targeted therapy and toripalimab (240 mg day 1) immunotherapy. In August 2020, the patient developed erythema and blisters around the umbilicus during hospitalization. After oral administration of loratadine tablets and topical use of mometasone furoate cream, the erythema and blisters subsided, and lenvatinib was discontinued. In September 2020, he was re-admitted to the hospital for immunotherapy with toripalimab. More than 10 days later, the patient's skin developed multiple ring-shaped erythemas, some of which were fused into pieces and scattered in blisters, with a tight blister wall and clear blister fluid. This was accompanied by erosion; mild exudation; and scabs on the head, face, neck, torso, upper limbs, buttocks, and thighs (Figure 1). Pathologically, the skin biopsy di-

agnosis was epidermal hyperplasia; focal sub-epidermal pustule formation; interface inflammation; spongy edema; lymphocyte infiltration; and a small number of plasma cells, consistent with drug-induced dermatitis (Figure 2). Immunofluorescence and other tests showed negativity for ANTI-desmoglein 1, ANTI-desmoglein 3, and BP180; positivity for DIF: linear IgG and C3; and negativity for both IgM and IgA and IIF: IgG, IgM, IgA, and C3, confirming the diagnosis of bullous pemphigoid (BP). The patient was started on 80 mg oral prednisone and 100 mg oral minocycline daily. After 3 days of therapy, the dose of oral minocycline was increased to 200 mg/day as new blisters continued to appear. The patient was also started on oral niacinamide 900 mg/day and oral niacinamide 500 mg/day as adjunctive therapies. No new blisters developed after 1 week of treatment, and thus, the medication was gradually discontinued. BP did not recur thereafter. The patient was followed up every 3 months, and the most recent MRI did not reveal significant progress in the mass.

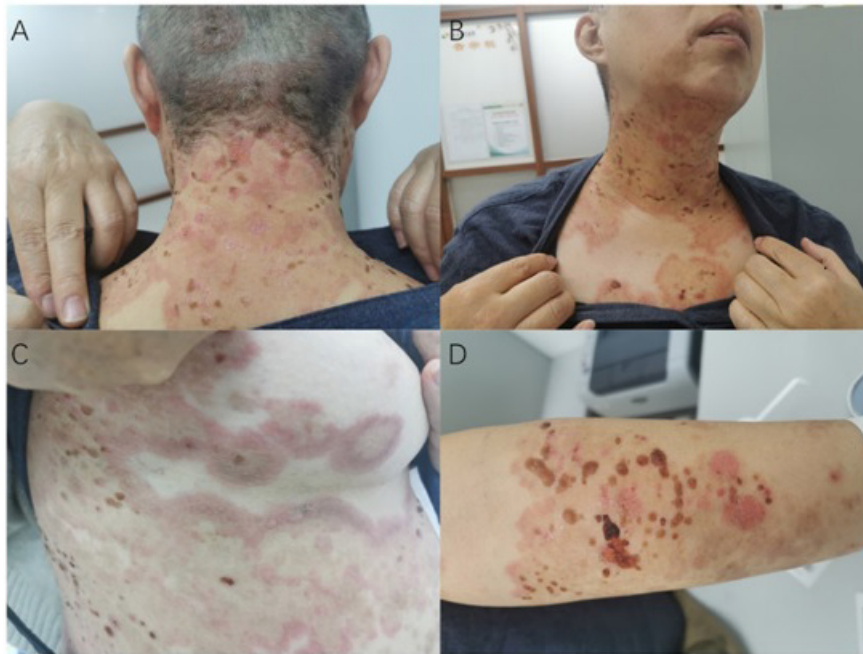

Figure 1. The patient's skin developed multiple ring-shaped erythema, scattered in blisters, accompanied by erosion and scab on the neck (A-B), head, torso (C), upper limbs (D).

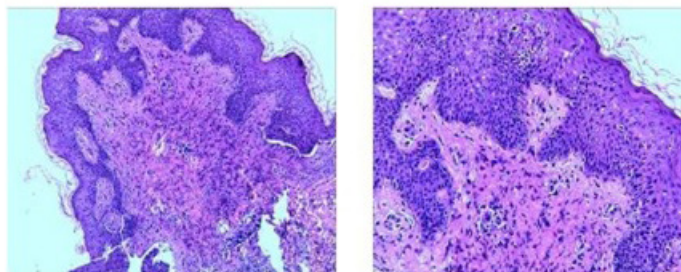


Figure 2. Histopathological of bullous pemphigoid.

4. Discussion

Adverse skin reactions are classified based on their toxicity. Grade I reactions mainly include rash or erythema without other related symptoms; grade II reactions cover less than 50% of the body surface area and include grade I reactions; and grade III reactions mainly include rash or blisters covering an area greater than 50%. Systemic ulcerative dermatitis or exfoliative dermatitis is a grade IV adverse skin reaction [4]. Most cases of adverse skin reactions after immunosuppressive agents are only grade I or II, and severe grade III and IV skin reactions are rarely reported [5-7]. Previous studies have reported an incidence rate of only 2.4-2.6% for severe (grade III and IV) immune-related adverse events (irAE) [8-10]. Rashes are common adverse skin reactions, with the typical rash being mild erythema or macular papules that are mainly distributed in the limbs and trunk. These usually appear within 2 weeks before treatment and can occur at any cancer stage [3,11,12]. Serious adverse skin reactions include bullous pemphigoid (BP), Stevens-Johnson syndrome (SJS), acute generalized exanthematous pustulosis (AGEP), and toxic epidermal necrolysis, but these are extremely rare [13-16]. Patients with BP have bursts of large and small bubbles with tight blister walls, accompanied by pruritus mainly distributed in the trunk and limbs [17]. The diagnosis of bullous pemphigoid is mainly based on histopathology and immunofluorescence. Histopathologic demonstrates a subepidermal blister. Inflammatory infiltration is usually pleomorphic, including neutrophils, eosinophils, and lymphocytes. Eosinophilic spongiosis or an infiltrate of eosinophils lining the basement membrane zone are typically observed. Direct immunofluorescence can detect IgG and/or C3 deposition at the basement membrane zone [18,19]. BP is caused by the autoimmune reaction of two hemidesmosomal proteins, BP180 and BP230 [20]. Meanwhile, severe cutaneous adverse reactions are rare, but their mortality rates are extremely high. SJS has a mortality rate of 10%, and 4% of cases of AGEP are life-threatening [21]. These conditions are further aggravated by serious clinical symptoms such as blisters, mucosal ulcers, or fever [3,22].

Although the pathogenesis of adverse skin reactions has not been fully clarified, it is generally believed that the PD-1 inhibitor pathway plays an important role in their occurrence. PD-1 inhibitors act on the surface of antigen-presenting cells in the initial and effector stages of T cell activation [23]. Only when the PD-1 inhibitor pathway is blocked that the body will produce an inflammatory response to the antigen. PD-1 inhibitors have been proven effective in the treatment of malignant tumors. It induces an anti-tumor response by releasing the negative regulation of the immune system, thereby reversing the inhibitory effects of T cells. Although PD-1 inhibitors are clinically effective for many cancers, they non-specifically activate the immune system, which may cause serious bullous pemphigoid. Bullous pemphigoid is

an autoimmune skin disease, which is related to the use of PD-1 inhibitors, including pembrolizumab, niluzumab, and teriprizumab [24,25]. In a research report, about 1% of patients developed bullous disease on PD-1 inhibitors treatment^[26]. PD-1 inhibitors may reduce the immunosuppressive effects of PD-1 receptor/PD-L1 ligand binding. Since PD-L1 ligands are also located on epithelial cells, these cells are attacked by the immune system and eventually lead to the development of bullous pemphigoid [27,28]. Skin-related adverse reactions usually occur within 1-2 weeks of PD-1 inhibitor treatment. Most patients have good prognosis, and mild symptoms can be easily controlled without the need for dose reductions in the immune checkpoint inhibitors. Meanwhile, the drug dosage should be carefully evaluated in patients who develop severe adverse skin reactions, and early identification and proper management are critical to the prognosis of these patients [29]. Mild rash or pruritus can be managed with a body cream or topical steroid. Under normal circumstances, it is not necessary to discontinue the immune checkpoint inhibitor to treat the mild rash or pruritus [23], but for serious adverse reactions (grade III or IV), oral high-dose corticosteroids (e.g., clobetasol), or oral antihistamines are needed [30,31]. In addition, keeping the patient's body clean and moist is also helpful for managing adverse skin reactions. Our patient showed atypical features. In general, skin-related adverse reactions generally occur after a few weeks of PD-1 inhibitor treatment [32]. However, our patient developed severe adverse skin reactions after 1 year of treatment with PD-1 inhibitors. Oxaliplatin + gemcitabine chemotherapy combined with lenvatinib targeted therapy and toripalimab immunotherapy had a significant benefit. The unresectable tumor before treatment became resectable after treatment. However, the patient also developed adverse skin reactions. Interestingly, a recent study on patients receiving nivolumab treatment found that the appearance of rash is a good prognostic factor. Patients with adverse skin reactions had higher disease-free survival and overall survival rates than did patients without adverse skin reactions [33,34]. In conclusion, although PD-1 inhibitors are effective, the risk-benefit ratio should be carefully considered in patients who develop severe-treatment related rash. The relationship between the efficacy of PD-1 inhibitors and the severity of the rash needs to be clarified in further studies.

5. Funding

The present study was supported by the Special Funding for Provincial Key R&D Project in 2019 (BE2019771) and the National Administration of Traditional Chinese Medicine (20085-9-3).

References

1. Lei X, Lei Y, Li JK. Immune cells within the tumor microenvironment: biological functions and roles in cancer immunotherapy. *Cancer Lett.* 2020; 470:126-133.
2. Sharma P, Allison JP. The future of immune checkpoint therapy. *Science.* 2015; 348: 56-61.

3. Sibaud V, Meyer N, Lamant L. Dermatologic complications of anti-PD-1/PD-L1 immune checkpoint antibodies. *Curr Opin Oncol.* 2016; 28: 254-263.
4. Jaber SH, Cowen EW, Haworth LR. Skin reactions in a subset of patients with stage IV melanoma treated with anti-cytotoxic T-lymphocyte antigen 4 monoclonal antibody as a single agent. *Arch Dermatol.* 2006; 142: 166-172.
5. Collins LK, Chapman MS, Carter JB. Cutaneous adverse effects of the immune checkpoint inhibitors. *Curr Probl Cancer.* 2017; 41: 125-128.
6. Belum VR, Benhuri B, Postow MA. Characterisation and management of dermatologic adverse events to agents targeting the PD-1 receptor. *Eur J Cancer.* 2016; 60: 12-25.
7. Michot JM, Bigenwald C, Champiat S. Immune-related adverse events with immune checkpoint blockade: a comprehensive review. *Eur J Cancer.* 2016; 54: 139-148.
8. Wang LL, Patel G, Chiesa-Fuxench ZC. Timing of onset of adverse cutaneous reactions associated with programmed cell death protein 1 inhibitor therapy. *JAMA Dermatol.* 2018; 154: 1057-1061.
9. Robert C, Long GV, Brady B. Nivolumab in previously untreated melanoma without BRAF mutation. *N Engl J Med.* 2015; 372: 320-330.
10. Weber JS, D'Angelo SP, Minor D. Nivolumab Versus Chemotherapy in patients with advanced melanoma who progressed after anti-CTLA-4 treatment (CheckMate037): a randomised, controlled, open-label, phase 3 trial. *Lancet Oncol.* 2015; 16: 375-384.
11. Lacouture ME, Wolchok JD, Yosipovitch G. Ipilimumab in patients with cancer and the management of dermatologic adverse events. *J Am Acad Dermatol.* 2014; 71: 161-169.
12. Minkis K, Garden BC, Wu S. The risk of rash associated with ipilimumab in patients with cancer: a systematic review of the literature and meta-analysis. *J Am Acad Dermatol.* 2013; 69: 121-128.
13. Sibaud V. Dermatologic reactions to immune checkpoint inhibitors: skin toxicities and immunotherapy. *Am J Clin Dermatol.* 2018; 19: 345-361.
14. Curry JL, Tetzlaff MT, Nagarajan P. Diverse types of dermatologic toxicities from immune checkpoint blockade therapy. *J Cutan Pathol.* 2017; 44: 158-176.
15. Weber JS, Kahler KC, Hauschild A. Management of immune-related adverse events and kinetics of response with ipilimumab. *J Clin Oncol.* 2012; 30: 2691-2697.
16. Naidoo J, Schindler K, Querfeld C. Autoimmune bullous skin disorders with immune checkpoint inhibitors targeting PD-1 and PD-L1. *Cancer Immunol Res.* 2016; 4: 383-389.
17. Siegel J, Totonchy M, Damsky W. Bullous disorders associated with anti-PD-1 and anti-PD-L1 therapy: a retrospective analysis evaluating the clinical and histopathologic features, frequency, and impact on cancer therapy. *J Am Acad Dermatol.* 2018; 79: 1081-1088.
18. Machado-Pinto J, McCalmont TH, Golitz LE. Eosinophilic and neutrophilic spongiosis: clues to the diagnosis of immunobullous diseases and other inflammatory disorders. *Semin Cutan Med Surg.* 1996; 15: 308-16.
19. Khandpur S, Verma P. Bullous pemphigoid. *Indian J Dermatol Venereol Leprol.* 2011; 77: 450-5.
20. Jung M, Kippes W, Messer G. Increased risk of bullous pemphigoid in male and very old patients: a population-based study on incidence. *J Am Acad Dermatol.* 1999; 41: 266-268.
21. Chen CB, Wu MY, Ng CY. Severe cutaneous adverse reactions induced by targeted anticancer therapies and immunotherapies. *Cancer Manag Res.* 2018; 10: 1259-1273.
22. Sibaud V. Dermatologic reactions to immune checkpoint inhibitors: skin toxicities and immunotherapy. *Am J Clin Dermatol.* 2018; 19: 345-361.
23. Rapoport BL, van Eeden R, Sibaud V. Supportive care for patients undergoing immunotherapy. *Support Care Cancer.* 2017; 25: 3017-3030.
24. Márquez-Rodas I, Cerezuela P, Soria A. Immune checkpoint inhibitors: therapeutic advances in melanoma. *Ann Transl Med.* 2015; 3: 267.
25. Lopez AT, Khanna T, Antonov N. A review of bullous pemphigoid associated with PD-1 and PD-L1 inhibitors. *Int J Dermatol.* 2018; 57: 664-669.
26. Siegel J, Totonchy M, Damsky W. Bullous disorders associated with anti-PD-1 and anti-PD-L1 therapy: a retrospective analysis evaluating the clinical and histopathologic features, frequency, and impact on cancer therapy. *J Am Acad Dermatol.* 2018; 79: 1081-1088.
27. Aggarwal P. Disproportionality analysis of bullous pemphigoid adverse events with PD-1 inhibitors in the FDA adverse event reporting system. *Expert Opin Drug Saf.* 2019; 18: 623-633.
28. Goletz S, Zillikens D, Schmidt E. Structural proteins of the dermal-epidermal junction targeted by autoantibodies in pemphigoid diseases. *Exp Dermatol.* 2017; 26: 1154-1162.
29. Sibaud V, Meyer N, Lamant L, Vigaros E, Mazieres J, Delord JP. Dermatologic complications of anti-PD-1/PD-L1 immune checkpoint antibodies. *Curr Opin Oncol.* 2016; 28: 254-63.
30. Sibaud V. Dermatologic reactions to immune checkpoint inhibitors: skin toxicities and immunotherapy. *Am J Clin Dermatol.* 2018; 19: 345-361.
31. Haanen JBAG, Carbonnel F, Robert C. Management of toxicities from immunotherapy: ESMO clinical practice guidelines for diagnosis, treatment and follow-up. *Ann Oncol.* 2017; 28: 119-142.
32. Friedman CF, Proverbs-Singh TA, Postow MA. Treatment of the immune-related adverse effects of immune checkpoint inhibitors: a review. *JAMA Oncol.* 2016; 2: 1346-1353.
33. Freeman-Keller M, Kim Y, Cronin H. Nivolumab in resected and unresectable metastatic melanoma: characteristics of immune-related adverse events and association with outcomes. *Clin Cancer Res.* 2016; 22: 886-894.
34. Sanlorenzo M, Vujic I, Daud A. Pembrolizumab cutaneous adverse events and their association with disease progression. *JAMA Dermatol.* 2015; 151:1206-1212.