

## A “3-Level Block” In AVNRT

Robaye B\*, Collet B and Xhaet O

Université catholique de Louvain, CHU UCL Namur, Service de cardiologie, Av. Docteur G. Thérasse 1, B5530 Yvoir, Belgium

### \*Corresponding author:

Robaye Benoit,  
Université catholique de Louvain, CHU UC Namur,  
Service de cardiologie, Av. Docteur G. Thérasse 1,  
B5530 Yvoir, Belgium,  
E-mail: benoit.robaye@uclouvain.be

Received: 01 Aug 2021

Accepted: 16 Aug 2021

Published: 21 Aug 2021

### Copyright:

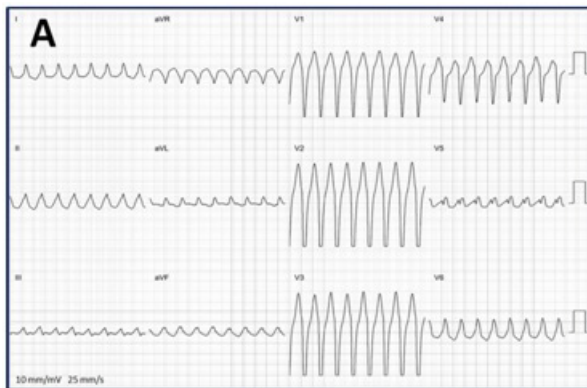
©2021 Robaye B. This is an open access article distributed under the terms of the Creative Commons Attribution License, which permits unrestricted use, distribution, and build upon your work non-commercially.

### Citation:

Robaye B, A “3-Level Block” In AVNRT. Ann Clin Med Case Rep. 2021; V7(4): 1-2

### 1. Clinical Image

A 29-year-old woman underwent electrophysiological study for paroxysmal wide-QRS tachycardia with a left bundle branch block (LBBB) aspect (Image A).



In a classical way, we inserted a duodecapolar catheter in the coronary sinus (mentioned as “Halo” on the endocavitary recordings, with Halo 3 at the ostium of the coronary sinus) and a quadripolar recording electrode was placed on the atrio-ventricular junction. Its distal recording pole is mentioned as HBE (His Bundle Electrogram) and proximal as AVN (Atrio-Ventricular Node).

We easily induced a typical (Slow/Fast) AVNRT that successively showed a conduction bloc at 3 different levels: First, a 2/1 supra-hissian block (Image B: only conducted atrial beats are followed by a Hiss deflection on AVN, red arrows). Next, a 2/1 infra-hissian block (Image C: each atrial beat is followed by a Hiss deflection). Finally, the arrhythmia converted into 1/1 conduction with LBBB (Image D). This last block reproduced the initial ECG aspect. You may see in this last recording that the H-V interval is a bit longer <http://acmcasereports.com/>

(51 vs 34 msec) due to the 1/1 conduction that slows down in the right bundle branch.

We ablated the slow pathway with no arrhythmia recurrence.

The originality of this case resides in this “3-level block” that was recordable during the same procedure. Also, AVNRT with 2/1 supra-hissian block, although already described, is not frequent, because the distal part of the AV node (ahead of the Hiss bundle) is often thought to be part of the arrhythmia circuit.

