

## A Rare Case of EBV Infection Mimicking Polymyositis with Hemophagocytic Syndrome-Diagnostic Challenges and Pitfalls

Li W<sup>1</sup>, Huang L<sup>2</sup>, Cheng T<sup>2</sup>, Pan Y<sup>2</sup> and Liao Z<sup>2\*</sup>

<sup>1</sup>Department of Pulmonary and Critical Care Medicine, the Third Affiliated Hospital of Sun Yat-sen University, Guangzhou, Guangdong 510630, China

<sup>2</sup>Department of Rheumatology and Immunology, the Third Affiliated Hospital of Sun Yat-sen University, Guangzhou, Guangdong 510630, China

### \*Corresponding author:

Zetao Liao,  
Department of Rheumatology and Immunology,  
the Third Affiliated Hospital of Sun Yat-sen  
University, No. 600 Tianhe Road,  
Guangzhou, Guangdong 510630, China,  
Tel: + 86 020-85252241, Fax: + 86 020-85252874,  
E-mail: zetaoliao@163.com

Received: 21 Mar 2021

Accepted: 03 Apr 2021

Published: 10 Apr 2021

### Copyright:

©2021 Liao Z. This is an open access article distributed under the terms of the Creative Commons Attribution License, which permits unrestricted use, distribution, and build upon your work non-commercially.

### Citation:

Liao Z. A Rare Case of EBV Infection Mimicking Polymyositis with Hemophagocytic Syndrome-Diagnostic Challenges and Pitfalls. *Ann Clin Med Case Rep.* 2021; V6(10): 1-3.

### 1. Abstract

To describe the clinical evolution of a case of Epstein-Barr virus infection simulating polymyositis from initial visit to final death

### 2. Case Report

A 17-year-old Chinese boy came to hospital in Sep 2018 for unregularly symmetrical muscle twitches and stiffness of limbs which disappeared within half an hour without medication. He had acne-form eruptions and edema of the face with migratory headache, oral ulcers and transient low-grade fever two months ago. In January 2019, he complained of right forearm swelling. He was otherwise feeling well with no systemic symptoms. Her family history was normal.

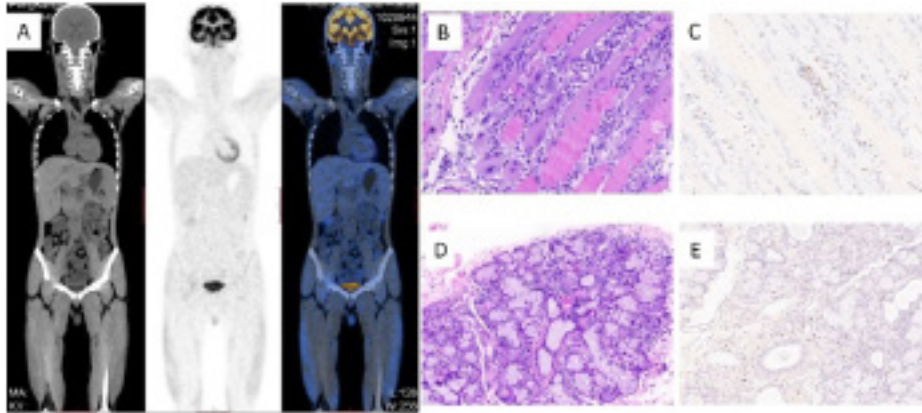
Laboratory investigations revealed bicytopenia (total white cell count  $2.62 \times 10^9/L$  and Red Blood Cell count  $3.36 \times 10^{12}/L$ ), abnormal liver function tests (AST 372 U/L [15–40], ALT 138 U/L [3–35]), raised lactate dehydrogenase (LDH) 1,160 U/L [71–231], and raised muscle enzymes (creatinine kinase 14,889 U/L [24–184] and Myoglobin (1,359.0 U/L [0–70.0])). C-reactive protein was not raised and blood culture showed no bacterial growth. A [<sup>18</sup>F] fluorodeoxyglucose positron emission tomography/computed tomography (FDG PET/CT) scan revealed splenomegaly and hepatomegaly changes. There were diffuse multiple FDG-avid muscle lesions scattered in the neck, chest, waist, buttock and

limbs. Small nodules were seen on bilateral skin of his face (SUVmax 2.0). Investigations of EBV antibody panel revealed elevated serum immunoglobulin titers of CA-IgG(>200), EA-IgG(139), EBNA-1-IgG(53). The myositis-specific antibodies were negative. Examination of hepatitis A, B, C, or D were negative as well. A biopsy of the left leg muscle and the labial gland was subsequently performed and revealed a multifocal, chronic inflammatory cell infiltration of small lymphocytes and neutrophils. The atrophic muscle fibers contain slightly basophilic cytoplasm and was consistent with a diagnosis of myositis. Plenty of plasma cells and lymphocytes infiltration aggregate in the interstitium (>50 foci in one field) of the labial and salivary gland. Bone marrow biopsy did not reveal any evidence of lymphoma or leukemia.

He received prednisolone and methotrexate treatment for the myositis and the CK decreased rapidly. In July 2nd 2019, his symptoms rapidly progressed with worsening of new onset of fever and jaundice for more than 1 month. At this point, EBV DNA level from the peripheral blood was significantly increased at  $5.67 \times 10^4$  copies viral DNA/ mL plasma. The leg muscle and labial gland biopsy was reviewed. The immunohistochemistry staining revealed co-expressed Epstein-Barr virus-encoded small RNA(EBER). Taken together, findings are consistent with EBV infection. We diagnosed his disease as chronic active EBV

infection from clinical findings and the antibody titer particular to EBV, EBER in the tissue and viral DNA in the blood. The patient's clinical condition deteriorated with worsening cytopenia and liver function, decreasing fibrinogen, high serum ferritin and LDH. Patient was treated empirically with intravenous Meropenem

and Caspofungin Acetate. A repeated bone marrow examination showed significant hemophagocytic activity. Hemophagocytic syndrome related gene test were negative. He finally developed fulminant hemophagocytic syndrome, rapidly deteriorated and died due to multiorgan failure in July 21st 2019.



**Figure 1**

(A) PET/CT scan showed multiple intensely FDG-avid muscle lesions scattered throughout the body, including muscles of the neck, chest, waist, buttock and limbs regions, SUVmax was 2.6 (right lateral thigh muscle).

(B) Left leg muscle lesions. Lesions revealed a multifocal, chronic inflammatory infiltration of small lymphocytes and neutrophils. The atrophic muscle fibers contains slightly basophilic cytoplasm and was consistent with a diagnosis of myositis (hematoxylin and eosin, 200×magnification).

(C) EBER (200×magnification) positive cells scattered between the muscle fibers.

(D) Labial and salivary gland lesions revealed plenty of plasma cells and lymphocytes infiltration aggregate in the interstitium (>50 foci in one field, hematoxylin and eosin, 200×magnification)

(E) EBER (200×magnification) positive cells scattered in the interstitium of the labial and salivary gland.

### 3. Discussion

Infection with Epstein-Barr virus (EBV) is common and induces a broad spectrum of illness. Approximately 90 to 95 percent of adults are EBV seropositive worldwide; however, in a large public university in the United States, the seroprevalence of EBV antibodies among entering freshman declined from 64 percent in 2006 to 52 percent in 2012 [1]. The popularity of myositis or hemophagocytic syndrome is very rare and unknown till now. Not to say the combination of EBV associated myositis and hemophagocytic syndrome.

In this case, however, despite a clinical picture of myositis, the cause of the muscle involvement was due to infiltration by EBV positive lymphocytes. EBV infection characteristically involve infectious mononucleosis. There are about 5 cases of B cell [2-7] lymphoma and 8 cases of T cell [8, 9] lymphoma reported before associated with both EBV and myositis as well as some gastric cancer, thyroid cancer and nasopharyngeal carcinoma [10-12]. Also, there are a few cases associated with muscle pathological evidence of myositis with chronic EBV infection [13, 14]. Almost all these patients went to death because of infection, DIC or multi-organ failure. What is striking in this case is that our patient had extensive and generalized muscle involvement and also hemophagocytic syndrome. Our patient also had an extremely

fulminant clinical course and he died just 8 months after initial presentation of the forearm swelling. This case also highlights several clinicopathologic diagnostic challenges. Clinically, this unusual case of EBV infection mimicked polymyositis and is firstly presented with initial muscle involvement and developed into hemophagocytic syndrome. The unusual clinical course of this patient offers different, although to a great extent speculative, explanations regarding the pathogenesis the interplay between EBV, myositis and hemophagocytic syndrome. Early diagnosis is important as EBV infection with predominant muscle involvement is associated with a fulminant clinical course. Histologically, the diagnosis on the muscle biopsy was challenging for several reasons. Firstly, the lymphoid infiltrate comprised mainly small lymphocytes without significant atypia. Secondly, this patient had no immune-disorder history. Thirdly, there were no autoantibodies including anti-Jo-1 antibodies, or extramuscular symptoms suggestive of polymyositis or dermatomyositis. Hence, performing a limited IHC without EBER, will not be helpful to diagnose EBV infection involving muscle.

Although a variety of therapeutic modalities have been applied, prolonged severe EBV infection is unlikely to be successfully treated. It is not known what could be the exact cause of myositis in these patients. In 1986 Walker and Jeffrey searched the

protein chain sequence mimicry of EBV and muscle proteins and put forward a hypothesis that may be the mechanism of the autoimmunity that invoke the virus associated myositis [15]. It may be a direct virus induced toxicity or, on the other hand, mediated by possible myotoxic effect of the antibodies elaborated as a consequence of the EBV infection. We hope future research will throw some light on this issue.

## References

- Dunmire SK, Verghese PS, Balfour HJ. Primary Epstein-Barr virus infection. *J CLIN VIROL*. 2018; 102: 84-92.
- Cooles FA, Jackson GH, Menon G, Isaacs JD. Epstein-Barr virus-driven lymphoproliferative disorder post-CAMPATH-1H (alemtuzumab) in refractory polymyositis. *Rheumatology (Oxford)*. 2011; 50: 810-2.
- Kamel OW, van de Rijn M, LeBrun DP, Weiss LM, Warnke RA, et al. Lymphoid neoplasms in patients with rheumatoid arthritis and dermatomyositis: frequency of Epstein-Barr virus and other features associated with immunosuppression. *HUM PATHOL*. 1994; 25: 638-43.
- Steff M, Le Corre Y, Penisson-Besnier I, Michalak S, Drossard G, et al. [Cutaneous EBV-associated lymphoproliferative disorder in a dermatomyositis treated with immunosuppressive agents]. *REV MED INTERNE*. 2009; 30: 720-3.
- Tournadre A, Amarger S, Joly P, D'Incan M, Ristori JM, et al. Polymyositis and pemphigus vulgaris in a patient: successful treatment with rituximab. *JOINT BONE SPINE*. 2008; 75: 728-9.
- Uchiyama T, Arai K, Yamamoto-Tabata T, Hirai K, Kishimoto K, et al. Generalized myositis mimicking polymyositis associated with chronic active Epstein-Barr virus infection. *J NEUROL*. 2005; 252: 519-25.
- Waldman MA, Callen JP. Self-resolution of Epstein-Barr virus-associated B-cell lymphoma in a patient with dermatomyositis following withdrawal of mycophenolate mofetil and methotrexate. *J AM ACAD DERMATOL*. 2004; 51: S124-30.
- Chan EH, Lu SJ, Petersson F, Tan KB, Chng WJ, et al. Unusual case of metachronous EBV-associated B-cell and NK/T-cell lymphoma mimicking polymyositis-diagnostic challenges and pitfalls. *AM J HEMATOL*. 2014; 89: 110-3.
- Ohtsuka M, Iwatsuki K, Kaneko R, Akiba H, Kikuchi S, et al. Epstein-Barr virus-associated lymphoid hyperplasia of the eyelid characterized by intramuscular infiltration. *Br J Dermatol*. 1999; 140: 358-9.
- Koppula BR, Pipavath S, Lewis DH. Epstein-Barr virus (EBV) associated lymphoepithelioma-like thymic carcinoma associated with paraneoplastic syndrome of polymyositis: a rare tumor with rare association. *CLIN NUCL MED*. 2009; 34: 686-8.
- Yamashita K, Hosokawa M, Hirohashi S, Arimura Y, Endo T, et al. Epstein-Barr virus-associated gastric cancer in a patient with dermatomyositis. *Intern Med*. 2001; 40: 96-9.
- Chen DY, Chen YM, Lan JL, Chen HH, Hsieh CW, et al. Polymyositis/dermatomyositis and nasopharyngeal carcinoma: the Epstein-Barr virus connection? *J CLIN VIROL*. 2010; 49: 290-5.
- Kobayashi N, Mitsui T, Ogawa Y, Iriuchishima H, Takizawa M, et al. A Rare Case of Chronic Active Epstein-Barr Virus (EBV) Infection Accompanied by the Infiltration of EBV-infected CD8+ T Cells into the Muscle. *J Pediatr Hematol Oncol*. 2018; 40: e171-5.
- Tsutsumi S, Ohga S, Nomura A, Takada H, Sakai S, et al. CD4-CD8-T-cell polymyositis in a patient with chronic active Epstein-Barr virus infection. *AM J HEMATOL*. 2002; 71: 211-5.
- Walker EJ, Jeffrey PD. Polymyositis and molecular mimicry, a mechanism of autoimmunity. *LANCET*. 1986; 2: 605-7.