

False Negative Results in Prenatal Aneuploidy Invasive Testing: Two Case Reports

Hamza A¹, Rachid M¹, Levy J¹, Drunat S², Bhattacharjee S¹, Marc A¹, Sibony O^{3,4}, Rosenblatt J³, Tabet A^{1,5*} and Dupont C^{1*}

¹Cytogenetic Unit-Department of Genetics, Robert-Debré University Hospital, Assistance-Publique Hôpitaux de Paris, Paris, France

²Genetic Biology Unit-Department of Genetics, Robert-Debré University Hospital, Assistance-Publique Hôpitaux de Paris, Paris, France

³Department of Gynecology and Obstetrics, Robert-Debré University Hospital, Assistance-Publique Hôpitaux de Paris, Paris, France

⁴Paris Diderot University, Sorbonne Paris Cité, Paris, France

⁵Neuroscience Department, Génétique Humaine et Fonction Cognitive Unit, Pasteur Institute, Paris, France

*Corresponding author:

Celine Dupont, Cytogenetic Unit -Department of Genetics, Robert-Debré University Hospital, Assistance-Publique Hôpitaux de Paris, Paris, France, Tel : (33) 1 40 03 40 93;
Fax: (33) 1 40 03 53 19,
E-mail: c.dupont@aphp.fr

Received: 05 Mar 2021

Accepted: 24 Mar 2021

Published: 30 Mar 2021

Copyright:

©2021 Dupont C et al., This is an open access article distributed under the terms of the Creative Commons Attribution License, which permits unrestricted use, distribution, and build upon your work non-commercially.

Citation:

Dupont C. False Negative Results in Prenatal Aneuploidy Invasive Testing: Two Case Reports. Ann Clin Med Case Rep. 2021; V6(9): 1-5.

Keywords:

Prenatal diagnosis; Aneuploidy; Cytogenetics; Chromosomal microarray; False negative

Authors Contribution:

Tabet A, Dupont C. These authors contributed equally to this paper

1. Abstract

1.1. Aims: Over the last decade, molecular methods, such as chromosomal microarray and Bacs-On-Beads assay, have been shown to improve the detection rate of chromosomal abnormalities. Nonetheless, conventional cytogenetics methods, such as FISH and karyotyping, are still useful tools and should not be dismissed.

1.2. Methods: We report on two complex prenatal diagnoses in which false-negative aneuploidy testing results were amended by conventional techniques. Diagnostic procedures were performed according to national guidelines and local protocols, using both molecular methods (chromosomal microarrays and Bacs-On-Beads assay) and conventional techniques (fluorescent in situ hybridization and karyotyping).

1.3. Results: In the first case, we show how trisomy 21/monosomy 21 mosaicism could not be detected by molecular methods due to quantitative compensation. In the second case, complex fetoplacental mosaicism, involving two trisomic (21 and 14) cell lines with opposite tissue distributions, impaired molecular diagnosis performance. In both cases, subsequent karyotyping and FISH

analysis permitted the correct diagnosis.

1.4. Conclusions: Cell cultures and single-cell assessment allowed by FISH and karyotyping were instrumental in characterizing the chromosomal abnormalities. These two cases illustrate the contribution of morphological cytogenetic analysis and cell cultures to the prenatal diagnosis of chromosomal abnormalities.

2. Introduction

Molecular methods demonstrate superior performance over conventional cytogenetics in the detection of chromosomal abnormalities. Bacs-on-Beads technology (BOBs) [1] and chromosomal micro arrays (CMA) [2] on native samples are progressively replacing conventional cytogenetic methods for invasive testing of high-risk pregnancies. BOBs is a multiplex, bead-based assay that uses a capture system of dye-tagged beads coated with bacterial artificial chromosomes targeting genomic regions of interests (e.g., chromosome 13, 18, 21 and microdeletion syndromes loci in the case of Prenatal BOBs and chromosome telomeres for Karyolyte BOBs) and a flow-cytometry type detection system [3]. Molecular methods are by nature quantitative; they assess the copy number

of multiple loci (from a few dozens in BOBs assays to hundreds of thousands in CMA) in DNA extracted from a sample, producing results averaged over millions of cells. Conversely, conventional cytogenetic methods qualitatively study chromosomal morphology at the single cell level. The trade-offs are a lower resolution in the case of karyotyping, a limited number of predetermined targeted loci in fluorescence in situ hybridization (FISH), and a relatively low number of cells studied in both.

While false-negative and false-positive, non-invasive prenatal testing results are the subject of intense interest [4-6], false-negative BOBs, CMA, or other quantitative molecular technologies results are rarely reported in the literature. It is important to be aware of the limitations of these assays to provide the most accurate information and the best care to expecting parents. We report on two cases illustrating the potential shortcomings of molecular methods.

3. Results - Clinical Reports

3.1. Case 1

The expecting mother was referred to our prenatal care center after abnormal second trimester ultrasonography results. At 26 weeks of gestational age (WG), ultrasonography showed evidence of a complex heart defect (tetralogy of Fallot, atrioventricular septal defect and two apical ventricular septal defects), absence of nasal bones and hydrops fetalis. Amniocentesis was performed. The observation of hydrops fetalis prompted the harvesting of fetal blood

(FB) for the purpose of metabolic screening.

Prenatal BOBs results on DNA extracted from uncultured amniotic fluid sample (AF) were normal (Figure 1, A). A few days later, karyotyping and FISH on FB cultures produced discordant results, with a dicentric chromosome 21 observed in all metaphases (Figure 1, B). Interphase FISH on the remaining volume of native amniocytes unexpectedly revealed the existence of two cellular populations, in equal proportions, displaying either one or three fluorescent signals (Figure 1, D). The final cytogenetic diagnosis was a mosaicism of two cell lines, one carrying a dicentric chromosome 21 and the other carrying a unique chromosome 21 (ISCN nomenclature: 46,XX,dic(21;21)(p11.2;p11.2)/45XX,-21), i.e., monosomy 21/trisomy 21 mosaicism. Identical results were obtained on a second, confirmatory amniocentesis. CMA (Agilent 8x60k) on uncultured AF returned normal results. Both parents' karyotypes and CMA results were normal.

Microsatellite markers analysis was performed on DNA extracted from uncultured FB and uncultured AF to rule out sample mislabelling. Semiquantitative analysis of fluorescence signals suggested a higher copy number of the chromosome 21 markers in fetal blood DNA but not in amniotic fluid DNA (Figure 1, E), in line with BOBs and CMA results on uncultured AF detailed above.

Following genetic counselling, the couple elected to carry the pregnancy to term. The child displayed a typical Down syndrome phenotype at birth. Post-natal genetic testing was forgone by pa-

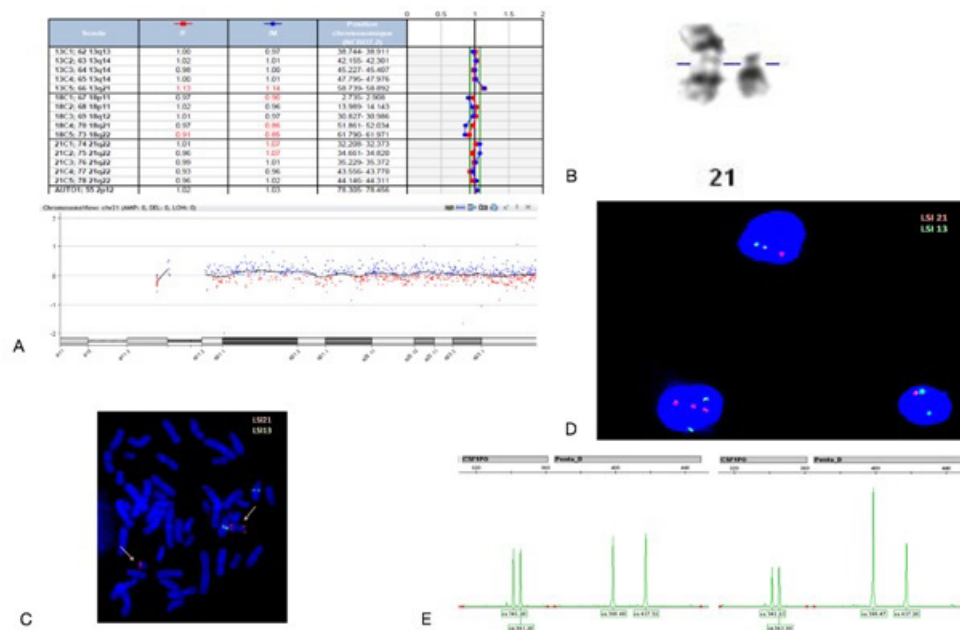


Figure 1: Molecular and conventional cytogenetics results in case 1. (A) *BOBs assay (top) and CMA (bottom) results over chromosome 21 for native AF sample. Fluorescence ratios show no elevation indicative of trisomy 21. (B) Partial G banded karyotype demonstrating the presence of a dicentric chromosome 21. (C) Metaphase FISH on FB cultures using LSI-21 (red) and LSI-13 (green) probes. Chromosomes 21 are indicated by red arrows showing one with two LSI-21 signals (right). (D) Interphase FISH on native AF sample using the same probes. Nuclei show either one (top, bottom left) or three (bottom right) chromosome 21 signals. (E) Two of the microsatellites analysed on native AF (left) and FB cultures (right). Semiquantitative analysis of signal intensity indicates a higher copy number of chromosome 21 microsatellites (penta D) in FB sample, suggesting trisomy 21.

rental decision.

3.2. Case 2

The patient was referred to our prenatal care center at 13 WG because of increased fetal* nuchal translucency (6.7 mm). Ultrasonography performed at 16 WG showed evidence of diaphragmatic hernia, walled hygroma, and bilateral jugular lymphatic sacs.

BOBs on DNA extracted from a native chorionic villi sample (CVS) showed a normal female profile, and notably no evidence of trisomy 21. CMA (Agilent CGH 8x60k) showed an elevated fluorescence log-ratio over chromosome 14, indicative of trisomy

14 (Figure 2, A). A few days later karyotyping on cultured CVS produced discordant results: trisomy 21/trisomy 14 mosaicism (47,XX,+21[19]/47,XX,+14[1]). Previous CMA results obtained on native CVS were carefully reviewed, and a homogenous, albeit minute, elevation of the fluorescence log-ratio over chromosome 21 could have indeed been suggestive of a low degree of trisomy 21 mosaicism—found among a majority trisomy 14 cells (Figure 2, A). Cytogenetic investigations results are summarized in Table 1. SNP-array (Infinium OmniExpress 24, Illumina) on native and cultured CVS confirmed trisomy 14 with a minor trisomy 21 fraction in native CVS, and trisomy 21 with a minor trisomy 14 frac-

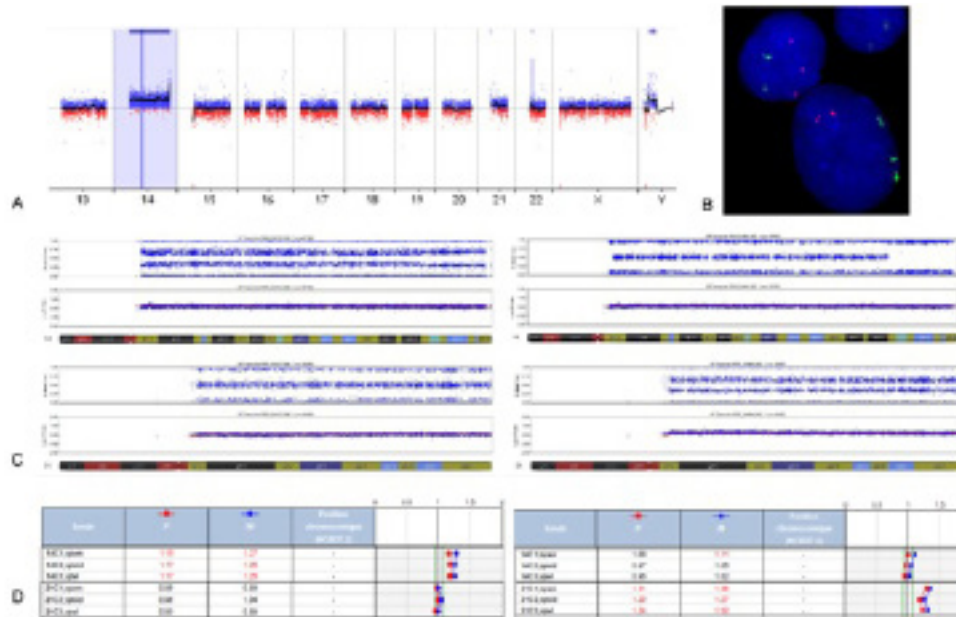


Figure 2: Molecular and FISH results in case 2. (A) CMA results on native CVS indicating trisomy 14, while chromosome 21 fluorescence log-ratio deviation from baseline is barely visible. (B) interphase FISH on CVS cultures using LSI-21 (red) and 14q telomeric (green) probes. The three red signals in the nuclei on the top left demonstrate the existence of a trisomy 21 cell line, while the three green signals on the nuclei on the bottom right are indicative of the presence of a trisomy 14 cell line. (C) SNP-array results over chromosome 14 (top) and 21 (bottom) on native CVS (left) and CVS cultures (right). B allele frequency and fluorescence log-ratio profiles are indicative of tissue-specific mosaicism: trisomy 14 with low fraction of trisomic 21 cells in native CVS and trisomy 21 with low fraction of trisomic 14 cells in CVS cultures. (D) *BOBs assay results on placenta (left) and fetal skin (right). Results are concordant with SNP-array profiles shown in (B), with native CVS and placenta, and CVS cultures and fetal tissues showing the same chromosomal aneuploidy, respectively trisomy 14 and trisomy 21. Of note, the low degree of mosaicism can be detected by SNP-array but not by *BOBs assay.

tion in cultured CVS (Figure 2, C). After receiving genetic counselling, the couple elected to terminate the pregnancy.

4. Discussion

We report on two cases of discrepancies between cytogenetic test results across different sample types and analytic methods, illustrating the complexity of results interpretation in prenatal diagnosis, especially in cases of mosaicism. These cases demonstrate how conventional cytogenetics is still a valuable tool for detecting and resolving unusually complex presentations.

Case 1 illustrates the inherent limitations of molecular methods quantitative nature, in that monosomic and trisomic cell lines balance each other out and produce a misleadingly normal profile. Only single-cell assessment by FISH and karyotyping provided a

correct cytogenetic diagnosis. Dicentric chromosomes are unstable, and either undergo centromere inactivation by alpha-satellite partial deletion to maintain themselves as functionally monocentric, or are lost during mitosis [7,8], explaining the presence of the monosomic cell line. A similar three cell line chromosome 21 aneuploidy has been described in the past [9], but, to our knowledge, this is the first report of the subsequent false-negative molecular results. A similar example of quantitative compensation involving submicroscopic abnormalities has been described by Malan *et al.* [10], in which a 2p25.3 duplication/2p25.3 deletion mosaicism could not be detected by CMA. Chromosomal mosaicism involving an autosomal structural abnormality is rare (a study found a frequency of 0.03% in a total of 179,663 amniocenteses (11)) and very few CMA false negative results are reported in the literature,

likely because it is indeed a reliable and accurate diagnostic tool [2]. Nonetheless, the diagnosis of copy-neutral chromosomal rearrangements and qualitative characterization of mosaicism at the single cell level elude BOBs and CMA, even though it can be clinically meaningful in prenatal diagnosis, as illustrated by our report.

Case 2 is a rare example of mosaicism involving two autosomal trisomies, and demonstrates the added value of maintaining cell cultures. Native and cultured CVS showed opposing degrees of trisomy 21/trisomy 14 mosaicism (5/95% vs. 70/30% respectively) over all analytic methods. Several scenarios could explain the presence of two distinct trisomic cell lines [12]. The most likely hypothesis, supported by FISH and karyotyping in the absence of parental origin analysis, is the occurrence of two independent mitotic errors and the selective proliferation of trisomic cell lines over the non-viable monosomic ones. Cytotrophoblast cells make up the bulk of the genetic material present in native CVS and are a closer reflection of placental tissues and conversely mesenchymal cells proliferate more readily *in vitro*, making cultured CVS a better reflection of embryonic tissues [13]. Results obtained from cell cultures were thus more informative regarding fetal status than molecular results on native samples.

Mosaicism is detected in approximately 1-2% of CVS and a majority of those cases (70-85%) are confined placental mosaicism (CPM). CPM is defined as a tissue specific mosaicism in which a chromosomal abnormality is present only in the placenta and absent in the fetus; conversely, in true fetal mosaicism the fetus carries the abnormal cell line [14]. Our case does not lend itself easily to simple classification; each trisomic cell line had a different tissue distribution, and it is difficult to distinguish between an actual low degree of mosaicism in a given tissue from a potential cross-tissue contamination. Prognosis (and thus genetic counseling) is heavily influenced by mosaicism type [15]. By leveraging the differential growth patterns of embryonic and extra-embryonic tissues to elucidate cell line distribution, cell culture is an invaluable tool in prenatal diagnosis.

5. Conclusion

Molecular tools have made the reliable diagnosis of homogeneous chromosomal abnormalities on native DNA routine. In the future, broader accessibility of next generation sequencing-based analysis for invasive and non-invasive testing, combining point mutations, aneuploidy, and CNV analysis will probably make CMA obsolete [16, 17]. But karyotyping and FISH on native and cultured cells is still a useful diagnostic complement, particularly in cases of complex mosaicisms that could be under-diagnosed by an exclusively molecular work-flow.

References

1. Choy KW, Kwok YK, Cheng YKY, Wong KM, Wong HK, Leung KO, et al. Diagnostic accuracy of the BACs-on-Beads™ assay versus karyotyping for prenatal detection of chromosomal abnormalities: a retrospective consecutive case series. *BJOG*. 2014; 121(10): 1245-1252.
2. Committee on Genetics, S. for M. M. Committee Opinion No.682 Microarrays and Next-Generation Sequencing Technology: The Use of Advanced Genetic Diagnostic Tools in Obstetrics and Gynecology. *Obstet Gynecol*. 2016; 128(6), e262-e268.
3. Vialard F, Simoni G, Aboura A, De Toffol S, Molina Gomes D, Marcato L, et al. Prenatal BACs-on-Beads™: a new technology for rapid detection of aneuploidies and microdeletions in prenatal diagnosis. *Prenat Diagn*. 2011; 31(5): 500-508.
4. Hartwig TS, Ambye L, Sørensen S & Jørgensen FS. Discordant non-invasive prenatal testing (NIPT) – a systematic review. *Prenat Diagn*. 2017; 37(6): 527-539.
5. Huijsdens-van Amsterdam K, Page-Christiaens L, Flowers N, Bonifacio MD, Ellis KMB, Vogel I, et al. Isochromosome 21q is over-represented among false-negative cell-free DNA prenatal screening results involving Down syndrome. *Eur J Hum Genet*. 2018; 26(10): 1490-1496.
6. Qi Z, Madaan S, Chetty S, Yu J & Wiita AP. False negative fetal cell free DNA screening for microdeletion syndromes in the presence of an unbalanced translocation involving monosomy 4p. *Prenat Diagn*. 2017; 37(4): 420-422.
7. Chiatante G, Giannuzzi G, Calabrese FM, Eichler EE & Ventura M. Centromere destiny in dicentric chromosomes: New insights from the evolution of human chromosome 2 ancestral centromeric region. *Mol Biol Evol*. 2017; 34(7): 1669-1681.
8. Stimpson KM, Matheny JE & Sullivan BA. Dicentric chromosomes: Unique models to study centromere function and inactivation. *Chromosome Res*. 2012; 20(5): 595-605.
9. Brisset S, Aboura A, Audibert F, Costa JM, L-Herminé AC, Gautier V, et al. Discordant prenatal diagnosis of trisomy 21 due to mosaic structural rearrangements of chromosome 21. *Prenat Diagn*. 2003; 23(6) : 461-469.
10. Rio M, Royer G, Gobin S, de Blois M, Ozilou C, Bernheim A, et al. Monozygotic twins discordant for submicroscopic chromosomal anomalies in 2p25.3 region detected by array CGH. *Clin Genet*. 2013; 84(1): 31-36.
11. Hsu LYF, Yu MT, Richkind KE, Van Dyke DL, Crandall BF, Saxe DF, et al. Incidence and significance of chromosome mosaicism involving an autosomal structural abnormality diagnosed prenatally

- through amniocentesis: A collaborative study. *Prenat Diagn.* 1996; 16(1): 1-28.
12. Huijsdens-van Amsterdam K, Barge-Schaapveld DQ, Mathijssen IB, Alders M, Pajkrt E & Knegt AC. Prenatal diagnosis of a trisomy 7/trisomy 13 mosaicism. *Molecular Cytogenetics.* 2012; 5(1): 8.
 13. Bianchi DW, Wilkins-Haug LE, Enders AC & Hay ED. Origin of extraembryonic mesoderm in experimental animals: Relevance to chorionic mosaicism in humans. *American Journal of Medical Genetics.* 1993; 46(5): 542-550.
 14. Grati FR, Malvestiti F, Branca L, Agrati C, Maggi F & Simoni G. Chromosomal mosaicism in the fetoplacental unit. *Best Pract Res Clin Obstet Gynaecol.* 2017; 42: 39-52.
 15. Izatt L. *Chromosome Abnormalities and Genetic Counseling: Fourth Edition.* *Clin Med.* 2012; 12(3): 297. doi.org/10.7861/clinmedicine.12-3-297.
 16. Badeau M, Lindsay C, Blais J, Nshimyumukiza L, Takwoingi Y, Langlois S, et al. Genomics-based non-invasive prenatal testing for detection of fetal chromosomal aneuploidy in pregnant women. *Cochrane Database Syst Rev.* 2017; 11(11): CD011767.
 17. Walker L, Watson CM, Hewitt S, Crinnion LA, Bonthron DT & Cohen KE. An alternative to array-based diagnostics: a prospectively recruited cohort, comparing arrayCGH to next-generation sequencing to evaluate foetal structural abnormalities. *J Obstet Gynaecol.* 2019; 39(3): 328-334.