

Dermoid Cyst of the Spermatic Cord Mimicking Incarcerated Inguinal Hernia

Sarmukh S*, Tan YL, Ramesh T and Chew LG

Department of General Surgery, Hospital Serdang, Selangor, Malaysia

*Corresponding author:

Sarmukh Singh,
Department of General Surgery, Hospital Serdang,
Selangor, Malaysia,
E-mail: sarmukh_rao@yahoo.com

Received: 24 Feb 2021

Accepted: 18 Mar 2021

Published: 23 Mar 2021

Copyright:

©2021 Sarmukh S et al., This is an open access article distributed under the terms of the Creative Commons Attribution License, which permits unrestricted use, distribution, and build up on your work non-commercially.

Keywords:

Dermoid cyst; Inguinal hernia; Surgical excision

Citation:

Sarmukh S. Dermoid Cyst of the Spermatic Cord Mimicking Incarcerated Inguinal Hernia. *Ann Clin Med Case Rep.* 2021; V6(6): 1-3.

1. Abstract

Dermoid cyst of the spermatic cord is a very rare clinical entity with only 6 cases reported in the literature so far. We describe an extremely rare case of a large dermoid cyst of the right spermatic cord measuring 6cm x 5cm x 5cm in an elderly patient who approached us with clinical manifestations of an incarcerated inguinal hernia. We advocate the treatment option is complete surgical excision of the dermoid cyst of the spermatic cord with mesh repairs. The use of polypropylene mesh, in emergency inguinal hernia repairs, associated with dermoid cyst is safe as it does not increase the rate of mesh infection.

2. Introduction

Most of masses located in the inguinal region in children correspond to inguinal indirect hernias, although other pathologic entities may be found, such as other types of hernias, inguinal cord cysts, undescended testis, adenopathies, varicoceles, hematomas, femoral artery aneurysms, varix or thrombophlebitis of the saphena vein, lipomas, lymphangiomas, angiomas of the round ligament, supernumerary pectineus bursa, pedunculated uterine fibroids, neuroblastoma metastasis, and epidermoid and dermoid cysts. Here by, we present a case of dermoid cyst of the spermatic cord in adult that presented with sign and symptoms of incarcerated Inguinal Hernia. We advocate the treatment option is complete surgical excision of the dermoid cyst of the spermatic cord with

mesh repairs. The use of polypropylene mesh, in emergency inguinal hernia repairs, associated with dermoid cyst is safe as it does not increase the rate of mesh infection.

3. Case report

A 58 year old Malay gentleman came to our emergency department with complains of swelling over the right inguinal scrotal region of two days duration which was progressively increasing in size associated with irreducibility. The patient denied symptoms of vomiting and bowel opening was normal. Clinical examination revealed patient was alert, conscious, well perfused. Examination of abdomen was soft, not distended, non tender. On the right inguinal region, there was a swelling measuring 5cm x 5cm which was irreducible with no overlying skin colour changes. Both testes were palpable. Contralateral side examination was normal. Our initial diagnosis was right incarcerated inguinal hernia. We Proceeded with an open hernia repair. During the operation, we noted that there were sac measuring 6cm x 5cm x 5cm at the distal end of the spermatic cord and during manipulate, jelly-like material expelled from it. The sac was dissected from the spermatic cord which was identified and preserved. Post operative diagnosis was an infected right spermatic cord cyst or spermatic lipoma. Histopathologic feature suggested a cyst, which is consistent with a benign inflamed cyst wall. The final diagnosis was dermoid cyst of the spermatic cord. Patient was well and was discharged on the 4th day of the surgery (Figure 1, 2).

Histopathology:

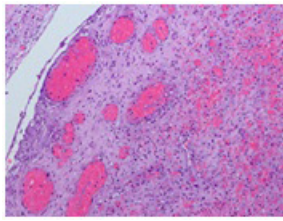


Figure 1: Testis / testicular adnexae finding is consistent with a benign inflamed cyst wall.

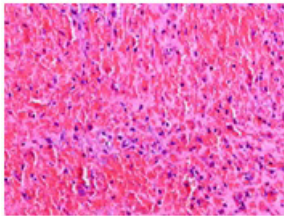


Figure 2: The tissue is devoid of epithelial lining. Granulation tissue formation is seen with reactive fibroblasts and prominent capillaries. No granuloma or malignancy seen.

4. Discussion

Inguinal-cord cysts are discovered in <1% of inguinal hernia dissections, and most of them are of mesothelial origin [1-3]. They may mimic incarcerations or contain unusual tissue elements.

Dermoid cyst as a cause of inguinal swelling is rare. A search of English medical databases, using key words dermoid cyst and inguinal mass, revealed 6 case reports of inguinal dermoid till date (Table 1) [4-6].

Dermoid cysts may be teratomatous or non teratomatous benign malformations. Non teratomatous dermoids are common in the inguinal canal. Grossly the excised tumour may be mistaken for a sebaceous cyst or epidermoids. The microscopic presence of skin along with its appendages and sebaceous gland differentiates them

from epidermoids and sebaceous cyst which have stratified squamous epithelium surrounded by fibrous tissue forming their wall [4-6]. Diagnosis is often mistaken clinically as irreducible inguinal hernia. Complications of the cyst which resembles obstructed or incarcerated inguinal hernia include inflammation and hemorrhage. The cyst may sometimes lead to compression of adjacent organs causing retention of urine and bowel obstruction. Possibility of malignant degeneration exists especially in women with dermoid cysts arising from round ligament. Tumour markers like alpha fetoprotein and beta chorionic gonadotropin estimation are helpful to monitor treatment and recurrence. Complete surgical excision is the treatment of choice. It is to be contemplated in order to avoid complications like inflammation, hemorrhage and rarely malignant degeneration [7].

According to a study by Georges et. al the polypropylene meshes can be safely used in inguinal hernia surgery, even when intestine resection is needed. The authors observed a lower recurrence rate in patients operated on with the Lichtenstein technique (tension-free) [8]. He concluded Mesh repairs can be safely performed when operating due to an incarcerated inguinal hernia. This also relates to other short- and long-term complications such as wound healing disorders, testicle hydrocoele, spermatic cord cyst, sexual dysfunction, seroma, haematoma and chronic pain [9]. The use of polypropylene mesh, in emergency inguinal hernia repairs, does not increase the rate of local complications. It seems that synchronous, partial resection of the small intestine, due to intestinal necrosis, is not a contraindication to use mesh.

D'Ambrosio et al. [10], in their study assessing the efficacy of polypropylene mesh in treating inguinal hernias, detected a beneficial influence of the polypropylene mesh structure on the rate of infectious complications. This is associated with the large diameter of pores (> 70 microns), which allows the macrophages and granulocytes to contact the bacteria.

Table 1: Published case reports of inguinal dermoid

Year	Author	Journal	Age (yrs)	Sex	Provisional Diagnosis	Duration of Mass
1963	Doctor HG et al. ⁷	J Int Coll Surg.	Inclusion dermoid cyst following repair of hernia with fullthickness skin graft.			
1971	Brightmore ²	BJCP	72	F	Strangulated hernia	4 Years
1985	Asraf et al. ^{*3}	JIMA	20	F	Lipoma	2 Years
1992	Leeming et al. ^{*4}	J Paed Surg	18	M	Incarcerated hernia	1 Years
2006	Genetzakis M et al. ¹	Clin Exp Obstet Gynecol	27	F	Cyst of round ligament	4 Years
2012 (Present Case)	Das et al.	IJCRI	48	M	Irreducible hernia	12 Years

5. Conclusion

We have presented a very rare case of a dermoid cyst of the spermatic cord in an adult patient mimicking incarcerated inguinal hernia. Although rare, this lesion must always be kept as a differential diagnosis while dealing with inguinal masses. The treatment of choice will be complete surgical excision of the dermoid cyst of

the spermatic cord with mesh repairs. The use of polypropylene mesh, in emergency inguinal hernia repairs, associated with dermoid cyst is safe as it does not increase the rate of mesh infection.

References

1. Salemis NS, Karagiouzis G, Sambaziotis D, Tsiambas E. Hernia Large dermoid cyst of the spermatic cord presenting as an incarcerated hernia: a rare presentation and literature review. 2010 Jun; 14(3): 321-3. doi: 10.1007/s10029-009-0542-x. Epub 2009 Aug 11.
2. Welch B, Barton TK. Inguinal cord cysts. *Hernia*. 2002; 6:33-35.
3. Vaos G, Zavras N, Velaoras K, Ereikat K, Mesothelial cyst of the spermatic cord as a cause of acquired cryptorchidism. *Hernia* 2008; 13(4): 439-41
4. Genetzakis M, Lagoudianakis EE, Papadima A, Tsekouras DK, Margogiannakis H, Filis K, et al. Inguinal dermoid cyst of the round ligament. A case report and review of the literature. *Clin Exp Obstet Gynecol* 2006; 33: 24951.
5. Brightmore T. Dermoid cyst of the inguinal canal simulating a strangulated inguinal hernia. *Br J Clin Pract* 1971; 25: 191.
6. Ashraf SM, Ansari BA, Iqbal N, Ansari A. Dermoid cyst of the inguinal canal. *J Indian Med Assoc*. 1985; 83: 1256.
7. Leeming R, Olsen M, Ponsky JL. Inguinal dermoid cyst presenting as an incarcerated inguinal hernia. *J Pediatr Surg*. 1992; 27: 1178.
8. Haapaniemi S, Nilsson E. Recurrence and pain three years after groin hernia repair. Validation of postal questionnaire and selective physical examination as a method of follow-up. *Eur J Surg*. 2002; 168: 22-8.
9. Lohsiriwat V, Sridermma W, Akaraviputh T. Surgical outcomes of Lichtenstein tension-free hernioplasty for acutely incarcerated inguinal hernia. *Surg Today*. 2007; 37: 212-4.
10. D'Ambrosio R, Capasso L, Sgueglia S. The meshes of polypropylene in emergency surgery for strangulated hernias and incisional hernias. *Ann Ital Chir*. 2004; 75: 569-73.