

Mesenteric Vein Thrombosis with Multiple Etiologies- A Rare Cause of Abdominal Pain During COVID Times

Mohammed AR^{1*}, Abubaker M¹, Hashmi HA², Hasan A¹, Hashmi T¹ and Zafar A³

¹Consultant Family Medicine, Primary Health Care Corporation, Qatar

²Medical Intern, Batterjee Medical College, Saudi Arabia

³Senior Consultant Internal Medicine, Hamad Medical Corporation, Qatar

*Corresponding author:

Abdul Rafi Mohammed,
Consultant Family Medicine,
Primary Health Care Corporation, Qatar,
E-mail: drmohdrafi@doctors.org.uk

Received: 17 Dec 2020

Accepted: 11 Jan 2021

Published: 14 Jan 2021

Copyright:

©2021 Mohammed AR et al., This is an open access article distributed under the terms of the Creative Commons Attribution License, which permits unrestricted use, distribution, and build upon your work non-commercially.

Citation:

Mohammed AR. Mesenteric Vein Thrombosis with Multiple Etiologies- A Rare Cause of Abdominal Pain During COVID Times. *Ann Clin Med Case Rep.* 2021; V5(7): 1-4.

Keywords:

Abdominal pain; Mesenteric vein thrombosis;
Hypercoagulability; Anticoagulation

1. Abstract

Acute mesenteric venous thrombosis is an uncommon cause of abdominal pain but can be potentially fatal if not diagnosed and treated early. We report an interesting case of a 33-year old lady who presented with mild abdominal pain to a designated COVID-19 center. She later presented to secondary care emergency department with worsening symptoms and was diagnosed to have superior mesenteric vein thrombosis due to multiple underlying etiologies. She was treated conservatively with anticoagulation and made a complete recovery. This case highlights the need to be vigilant about rare conditions presenting with common symptoms especially where clinical services are focused on a pandemic.

2. Introduction

Acute mesenteric venous thrombosis (MVT) is a rare diagnosis but can be a life-threatening cause of abdominal pain accounting for 6–9% of all mesenteric ischemia [1]. It has a reported incidence rate of 0.002%–0.06% in hospital admissions and was first identified in 1895 [2]. It presents with non-specific signs and symptoms, the diagnosis of which requires a high index of suspicion [3]. Thrombosis usually is in the superior mesenteric vein, but rarely the inferior mesenteric vein can also be involved. The diagnosis is confirmed radiologically on CT scanning with intravenous contrast.

3. Case Presentation

A 33-year old lady presented to a designated Coronavirus Disease (COVID) primary health care center with a two-day history of mild central abdominal pain radiating to both flanks associated with nausea. She had no other systemic symptoms of note. On examination her temperature was 39 Celsius, heart rate regular at 123 beats per minute with normal

oxygen saturation. She had minimal central abdominal tenderness with normal audible bowel sounds, and rest of the systemic examination was unremarkable. A chest X-ray, CBC, renal panel, liver function tests and urine analysis were all normal apart from a mildly raised CRP of 17. She was treated symptomatically with paracetamol and 500 ml of intravenous normal saline, and her vital parameters improved. A presumed diagnosis of gastroenteritis was made as her symptoms started after she had eaten out a day before. She was discharged home as she felt better. A routine Severe Acute Respiratory Syndrome Coronavirus 2 (SARS-CoV-2) swab was taken prior to discharge and was later reported negative.

Two days later, she presented to the local hospital emergency department due to worsening abdominal pain. Her vital parameters were stable during this presentation. She gave a history of appendicitis twenty years ago which was complicated with peritonitis and perforation. The patient was not aware of the exact diagnosis at that time. She was not on any regular medication or oral contraceptives, had no significant family history of note, was a nonsmoker and consumed no alcohol. She worked as a secretary and had completed her family having four children already. Abdominal examination during this admission revealed minimal tenderness in the epigastrium and umbilical region, normal bowel sounds and no evidence of guarding, rigidity or distension. She was initially treated with analgesia, intravenous fluids and Pantoprazole.

Standard blood investigations (Table 1) showed a mild rise in CRP, liver enzymes and Prothrombin time (PT). Arterial blood gas analysis was normal with no evidence of metabolic acidosis. Protein C and S levels were also requested at the time which were later reported to be low. Anti-cardiolipin antibodies and other connective disease specific antibodies were negative. Blood, urine and stool cultures did not reveal any growth of

microorganisms, and stool for occult blood was negative. A repeat SARS-Co-V-2 was done and was negative again.

An abdominal ultrasound was done on day one of admission which was reported normal with no evidence of acute cholecystitis, portal vein abnormality or liver abscess. A CT abdomen done on the same day showed a filling defect in the tributary of the superior mesenteric vein (Figure 1) suggestive of superior mesenteric vein thrombosis (SMVT), and bowel wall thickening in the distal ileum involving the ileocecal junction suggestive of inflammatory bowel disease.

Following this report, she was started on a therapeutic dose of Enoxaparin, Ciprofloxacin and Metronidazole. A surgical consultation advised conservative management as there was no radiological or biochemical evidence

Table 1: Important lab results from day 1 of admission

Test	Result	Reference interval
Hemoglobin	13.2	12.0-15.0
White Blood count	6.4	4.0-10.0
Platelets	165	150-400
Urea	1.6	2.8-8.1
Creatinine	58	44-80
Lactic acid	1	0.5-2.2
C-reactive protein	83.8*	0.0-5.0
Bilirubin	21	0-21
Alkaline Phosphatase	157	35-104
Alanine aminotransferase	62*	0-33
Aspartate transaminase	43	0-32
Amylase	14	13-53
Prothrombin time	13.8*	9.7-11.8
Activated partial thromboplastin time	32.5	24.6-31.2
Protein C	68.8*	70.0-140.0
Protein S	37.6*	56.1-126.0

*Results out of normal lab range values

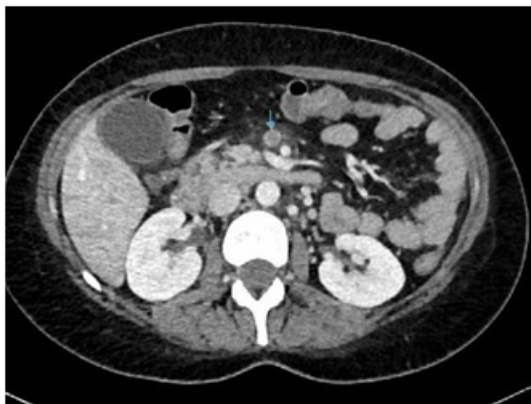

Figure 1: showing Mesenteric Vein thrombosis (marked with arrow)

of infarcted bowel. A follow up CT angiogram the next day confirmed the diagnosis of SMVT. Prior to discharge she was started on warfarin and has been doing well with regular follow up in anticoagulation clinic.

4. Discussion

4.1. Etiology

MVT can be associated with several underlying conditions and can rarely be idiopathic too. Common etiologies for MVT are hypercoagulable states, local vessel wall injury and venous stasis (Table 2)

An interesting finding in the investigation panel in our case was that the

protein C and protein S were low indicating an inherited thrombophilic tendency. Hypercoagulability has been found to be the commonest reason for isolated MVT in retrospective case analyses [4]. In addition to the above-mentioned causes, lately there have been sporadic case reports of COVID-19 associated mesenteric vein thrombosis [5]. However, this patient tested negative for SARS-Co-V-2 twice with a reverse transcriptase polymerase chain reaction (Rt-PCR) test.

Inflammatory bowel disease (IBD), a known cause, is a potential cause of MVT in this patient in addition to the underlying prothrombotic condition. In a Swiss IBD cohort study, mesenteric vein thrombosis was reportedly more frequent than originally thought. The study showed that thromboses were more peripheral, chronic and difficult to identify on CT Scanning with intravenous contrast. Generally, they had more severe IBD and a more complicated clinical outcome [6].

Mildly abnormal liver enzymes with raised PT were noted in our patient. Portal vein thrombosis (PVT) associated with MVT can happen even though this was not the case in our patient. Liver cirrhosis associated portal vein thrombosis has been often reported along with mesenteric vein thrombosis [7].

In summary the reason for mesenteric vein thrombosis in this case seems to be multiple with thrombophilia, inflammatory bowel disease and previous surgery all contributing to the pathology. There have been no similar case reports in the literature as far as we are aware, with similar three underlying etiologies present in a single patient.

4.2. Presentation

The condition often presents with abdominal pain, as noted in this case. Usually presentation is nonspecific with a variable degree of abdominal pain that may not necessarily correlate with the examination findings. These factors can result in delayed or missed diagnosis [8]. Patients may present with vague and misleading other symptoms such as nausea, vomiting, hematemesis, constipation or diarrhea and melaena. Fever can indicate infection or an underlying inflammatory process [9]. In our case, fever was likely to be from an inflammatory bowel process as evident from the raised inflammatory markers and CT findings which responded well to antibiotics. Even though the incidence of occult blood in stool has been reported to be 50% in cases of MVT [10], our patient had a negative stool test.

4.3. Investigations

The gold standard investigation for diagnosis is CT scanning with intravenous contrast. The typical finding noted is the presence of thrombus within the vein, visible as a focal translucency. Also, transabdominal color Doppler ultrasound can aid in the diagnosis of large thrombus but may not pick up thrombus in vessels which are smaller [11]. Nuclear scintiangiography has a lower sensitivity of 75% to pick up MVT [12], though easier to perform from the patient's perspective it is not widely available.

The role of hematological parameters to aid in diagnosis of acute mesenteric ischemia is debatable. White blood cell count and neutrophil-to-lymphocyte ratio, mean platelet volume, lactate dehydrogenase, serum lactate, D-dimer, red cell distribution width and transaminases have been suggested as markers of disease severity rather than diagnosis [13].

4.4. Management

Management depends on severity of clinical presentation and the main aim of treatment immediately is to prevent further spread of thrombus and avoid intestinal infarction. The long term goal is to prevent recurrent thrombosis (Figure 2).

4.4.1. Conservative Therapy

Anticoagulation is the corner stone of non-interventional therapy. Prompt and prolonged anticoagulation reduces mortality and length of hospital stay. Our patient had subcutaneous heparin followed by warfarin on discharge which is the standard recommended management. Newer oral anticoagulants lack specific studies looking at their efficacy in treating MVT [14].

4.4.2. Surgical Management

Non-surgical management improves survival and has less complications

when compared to a surgical approach. Surgical management is indicated in patients who are hemodynamically unstable, have peritonitis or bowel infarction [15]. Resection of necrotic bowel followed by anastomosis is the recommended procedure in such cases.

4.4.3. Interventional Radiological Procedures

Patients who have persistent symptoms or if the abdominal pain does not settle 48-72 hours after starting anticoagulation, or those who develop signs of peritonitis and are not fit for surgical interventions should be considered for interventional radiological procedures which mostly includes catheter-directed fibrinolysis and/or thrombectomy [16]. Thrombectomy is most effective in cases of acute thrombosis and the procedures include percutaneous mechanical thrombectomy, angioplasty with stenting and suction thrombectomy. Other interventional procedures include transjug-

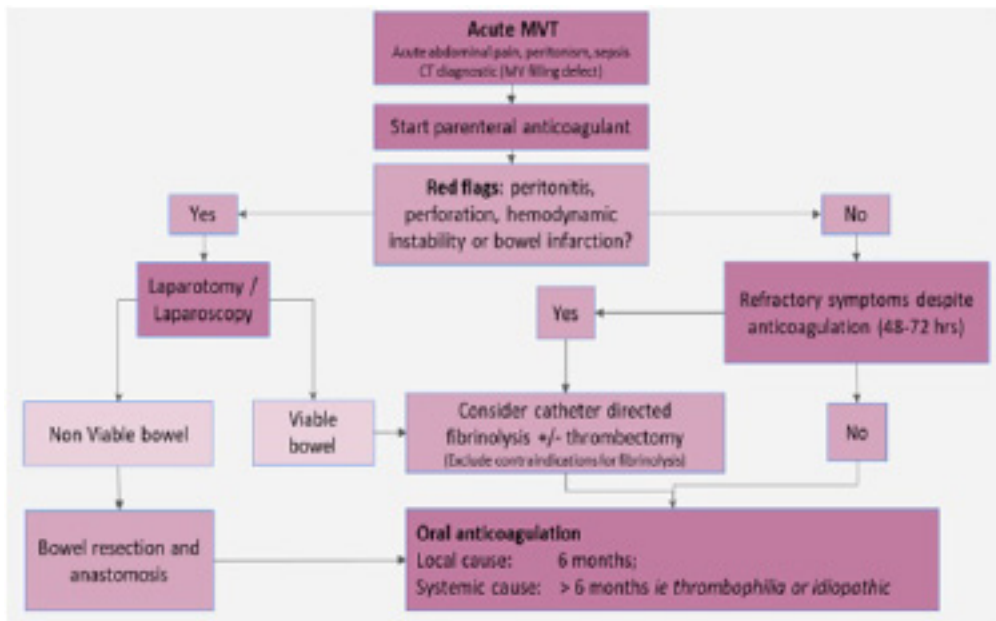


Figure 2: Summary management of Mesenteric Vein Thrombosis

Inherited thrombophilia	Protein C or S deficiency
	Antithrombin deficiency
	Factor V Leiden deficiency
	Prothrombin gene mutation
Acquired thrombophilia due to hematologic conditions	Polycythemia rubra vera
	Myelofibrosis
	Thrombocytopenia
	JAK2 mutation in
	latent myeloproliferative disorders
Acquired thrombophilia due to nonhematologic conditions	Antiphospholipid antibodies
	Paroxysmal nocturnal hemoglobinuria
	Malignancy especially
	pancreatic origin
Local inflammatory conditions causing vessel wall injury	Oral contraceptive pills
	Pregnancy
	Nephrotic syndrome
	Inflammatory bowel disease
	Appendicitis
Other causes of vessel wall injury	Diverticulitis
	Peritonitis
	Pancreatitis
	Intra-abdominal surgery particularly splenectomy
	Abdominal trauma

Table 2: Possible causes for Mesenteric vein thrombosis

ular intrahepatic portosystemic shunt (TIPSS) and intravascular thrombolytic therapy [17].

Contraindications for catheter-directed fibrinolysis include history of stroke or intracranial hemorrhage, primary or metastatic malignancy of central nervous system, active or recent bleeding, recent surgery, recent trauma, and mesenteric infarction [18].

5. Prognosis

Earlier studies had shown significant mortality in MVT patients with reported rates of up to 20% [19]. Poor outcomes correlated to duration of symptoms, increasing age and any underlying malignancy. But newer modalities of diagnosis and early intervention have improved the overall survival rates [20].

6. Conclusion

A high index of suspicion is needed to diagnose acute mesenteric venous thrombosis due to its non-specific and variable clinical presentation. Accurate and early diagnosis as well as timely management is the key factor to reduce morbidity and mortality associated with this condition. The long term outcome not only depends on the site and extension of thrombosis but also on presence of any underlying etiological factors [21].

References

1. Sulger E, Dhaliwal HS, Goyal A, Gonzalez L. Mesenteric Venous Thrombosis. In: StatPearls. StatPearls Publishing, Treasure Island (FL); 2020.
2. Ottinger LW, Austen WG. A study of 136 patients with mesenteric infarction. *Surg Gynecol Obstet.* 1967; 124(2): 251-61.
3. Harnik IG, Brandt LJ. Mesenteric venous thrombosis. *Vasc Med.* 2010; 15(5): 407-18.
4. Kumar S, Kamath PS. Acute superior mesenteric venous thrombosis: one disease or two? *Am J Gastroenterol.* 2003; 98(6): 1299-304.
5. Filho AC, Cunha BS. Inferior mesenteric vein thrombosis and COVID-19. *Rev Soc Bras Med Trop.* 2020; 53: e20200412.
6. Violi NV, Schoepfer AM, Fournier N, Guiu B, Bize P, Denys A, et al. Swiss Inflammatory Bowel Disease Cohort Study Group. Prevalence and clinical importance of mesenteric venous thrombosis in the Swiss Inflammatory Bowel Disease Cohort. *AJR Am J Roentgenol.* 2014; 203(1): 62-9.
7. Tripodi A, Mannucci PM. The coagulopathy of chronic liver disease. *N Engl J Med.* 2011; 365(2): 147-56.
8. Divino CM, Park IS, Angel LP, Ellozy S, Spiegel R, Kim U. A retrospective study of diagnosis and management of mesenteric vein thrombosis. *Am J Surg.* 2001; 181(1): 20-3.
9. Ozaras R, Mete B, Hakko E, Mert A, Tabak F, Bilir M, et al. Primary antiphospholipid syndrome: a cause of fever of unknown origin. *Intern Med.* 2003; 42(4): 358-61.
10. Boley SJ, Kaley RN, Brandt LJ. Mesenteric venous thrombosis. *Surg Clin North Am.* 1992 Feb;72(1):183-201.
11. Kidambi H, Herbert R, Kidambi AV. Ultrasonic demonstration of superior mesenteric and splenoportal venous thrombosis. *J Clin Ultrasound* 1986; 14: 199-201.
12. Harnik IG, Brandt LJ. Mesenteric venous thrombosis. *Vasc Med* 2010;15(5):407-418.
13. Khan SM, Emile SH, Wang Z, Agha MA. Diagnostic accuracy of hematological parameters in acute mesenteric ischemia-a systematic review. *Int J Surg* 2019; 66: 18-27.
14. Maan A, Padmanabhan R, Shaikh AY, Mansour M, Ruskin JN, Heist EK. Newer anticoagulants in cardiovascular disease: a systematic review of the literature. *Cardiol Rev.* 2012; 20(5): 209-21.
15. Chen C. Direct thrombolytic therapy in portal and mesenteric vein thrombosis. *J Vasc Surg.* 2012; 56(4): 1124-6.
16. Hmoud B, Singal AK, Kamath PS. Mesenteric venous thrombosis. *J Clin Exp Hepatol.* 2014; 4(3): 257-63.
17. Singal AK, Kamath PS, Tefferi A. Mesenteric venous thrombosis. *Mayo Clin Proc.* 2013; 88(3): 285-94.
18. Kim HS, Patra A, Khan J, Arepally A, Streiff MB. Transhepatic catheter-directed thrombectomy and thrombolysis of acute superior mesenteric venous thrombosis. *J Vasc Interv Radiol.* 2005; 16(12): 1685-91.
19. Hedayati N, Riha GM, Kougiyas P, Huynh TT, Cheng C, Bechara C, et al. Prognostic factors and treatment outcome in mesenteric vein thrombosis. *Vasc Endovascular Surg.* 2008; 42(3): 217-24.
20. Salim S, Zarrouk M, Elf J, Gottsäter A, Ekberg O, Acosta S. Improved Prognosis and Low Failure Rate with Anticoagulation as First-Line Therapy in Mesenteric Venous Thrombosis. *World J Surg.* 2018; 42(11): 3803-3811.
21. Ageno W, Dentali F, Squizzato A. How I treat splanchnic vein thrombosis. *Blood.* 2014; 124(25): 3685-91.