

## A Rare Translocation of t (1, 5) (q21, q32) in a Case of Myeloid Neoplasm With Eosinophilia

Wu M, Zhu Y, Zhang Y, Tang L, Zhao H, Li J and Chen Y\*

Shanghai Institute of Hematology, State Key Laboratory of Medical Genomics, National Research Center for Translational Medicine at Shanghai, Ruijin Hospital Affiliated to SJTUSM, Shanghai, China

### \*Corresponding author:

Yu Chen,  
Shanghai Institute of Hematology,  
State Key Laboratory of Medical Genomics,  
National Research Center for Translational  
Medicine at Shanghai, Ruijin Hospital Affiliated to  
SJTUSM, Shanghai, China,  
E-mail: [cy10638@rjh.com.cn](mailto:cy10638@rjh.com.cn)

Received: 12 Dec 2020

Accepted: 30 Dec 2020

Published: 06 Jan 2021

### Copyright:

©2021 Chen Y et al., This is an open access article distributed under the terms of the Creative Commons Attribution License, which permits unrestricted use, distribution, and build upon your work non-commercially.

### Citation:

Chen Y. A Rare Translocation of t (1, 5) (q21, q32) in a Case of Myeloid Neoplasm With Eosinophilia. *Annals of Clinical and Medical Case Reports*. 2021; V5(6): 1-4.

### Keywords:

Myeloid neoplasm with eosinophilia; PDGFRB; TPM3

### 1. Abstract

Myeloid neoplasm with eosinophilia is a kind of unusual hematological malignancy. Back in the morphological diagnosis era, the prognosis was generally poor and the best treatment for these cases was allo-stem cell transplantation. According to the classification of eosinophilic diseases revised in the 2008 WHO scheme of myeloid neoplasms and reaffirmed in 2016, more detailed cytogenetic rearrangement and molecular mutations were included in the diagnosis and treatment algorithm. Here we report a case with a rare rearrangement of PDGFRB, further demonstrated with a TPM3-PDGFRB fusion gene, leading to myeloid neoplasm with eosinophilia and responding greatly to imatinib treatment. As the N-terminal of TPM3 could be auto-dimerized, the TPM3-PDGFRB fusion protein appeared as dimer, mediating the excessive activation of the PDGFRB signal pathway. Since given genetic disorders were targetable with tyrosine kinase inhibitors, despite of the low mutated rate, the early and precise detection of the possible genetic abnormality is extremely significant in the diagnosis and treatment of patients.

### 2. Introduction

Eosinophilia was seen in multiple occasions. It is defined as the absolute eosinophils counts was more than  $500/\text{mm}^3$  in the peripheral blood. Based on the upregulated reason, the eosinophilia could be assigned into three groups, which are reactive, clonal (primary) and idiopathic eosinophilia. For the reactive eosinophilia, in which condition the eosinophils appear with normal morphology and are

multiclonal, is usually a reactive response to infections like tissue-invasive parasites or allergic conditions [1].

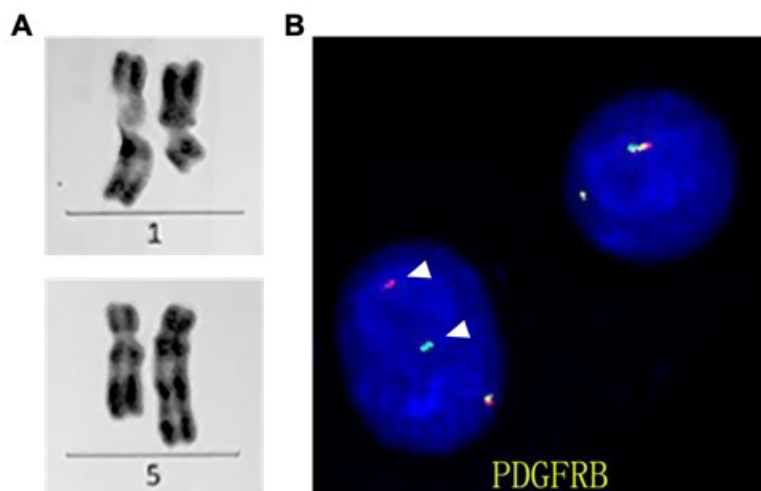
Regarding to the clonal eosinophilia, it belongs to myeloid neoplasm according to the revised 2016 WHO classification of myeloid neoplasm. Based on the existence of specific molecular mutation, Myeloid/lymphoid neoplasms associated with eosinophilia and rearrangement of PDGFRA, PDGFRB, or FGFR1, or with PCM1-JAK2, Chronic eosinophilic leukemia, not otherwise specified [2]. Previously, this neoplasm was cited as an aggressive disease with a median overall survival of less than 2 years. However, after the universal initiation of imatinib as standard therapy, a recent study reported 10-year overall survival of 90% [3]. As certain molecular abnormalities were closely related to targeted therapy, the early and precise diagnosis was urgent to be made.

### 3. Case Presentation

A 21-year-old young man with abdominal pain for a month, accompanied with fever and ostalgia. On examination, he had massive splenomegaly. He has no family history of hematologic disorders. His laboratory tests including complete blood count (CBC) showed hemoglobin of 103g/L, a platelet count of  $77 \times 10^9/\text{L}$ , and a leukocyte count of  $68.25 \times 10^9/\text{L}$  with segmented neutrocyte 44%, lymphocyte 8%, monocyte 5%, eosinophilic granulocyte 38%, early young grain 2%, neutral medium grain 2%, neutral late young grain 1%. Additional workup showed elevated iron stores (Ferritin 433.2ng/ml), markedly increased vitamin B12 level ( $>1500 \text{ pg/mL}$ ). Abdominal imaging confirmed massive splenomegaly. PET/

CT examination showed a massive elevated metabolism rate in bone and mild increased metabolism in spleen, enlarged superficial lymph node in neck and groin. On bone marrow examination, it revealed a hypercellular marrow with increased eosinophils (26%). Cytoflow test showed 35% of eosinophils and no abnormal plasma cells. Bone marrow examination showed hyperplastic marrow, increased proportion of granulocytes, apparent visible eosinophils and decreased megakaryocytes. Conventional cytogenetics

demonstrated a t (1;5) (q21; q32) (Figure 1A) in 10 metaphases out of 11 and fluorescence in situ hybridization (FISH) confirmed a PDGFRB rearrangement (Figure 1B). FISH was negative for FGFR1 8P11, and FIP1L1-CHIC2-PDGFR A 4q12 rearrangements. BCR-ABL (P190, P230, P210), ETV6-PDGFR $\beta$ , PCM/JAK2, W515L, JAK2V617F, FIP1L1/PDGFR $\alpha$ , JAK2EXON12, CALREXON9 mutation analysis performed by qualitative, allele-specific polymerase chain reaction (PCR) assay was negative.



**Figure 1:** Identification of the chromosome alteration

(A) R-banding karyotypic analysis of the diagnostic BM of the patient revealed the t(1,5)(q21;q33) (B) FISH identifies the breakpoints in chromosomes 5. The red/green signal showed the normal PDGFRB gene with the probes designed between 5q32-q33. The separate color of 5' PDGFRB (green) and 3' PDGFRB (red) showed a break of the PDGFRB gene location.

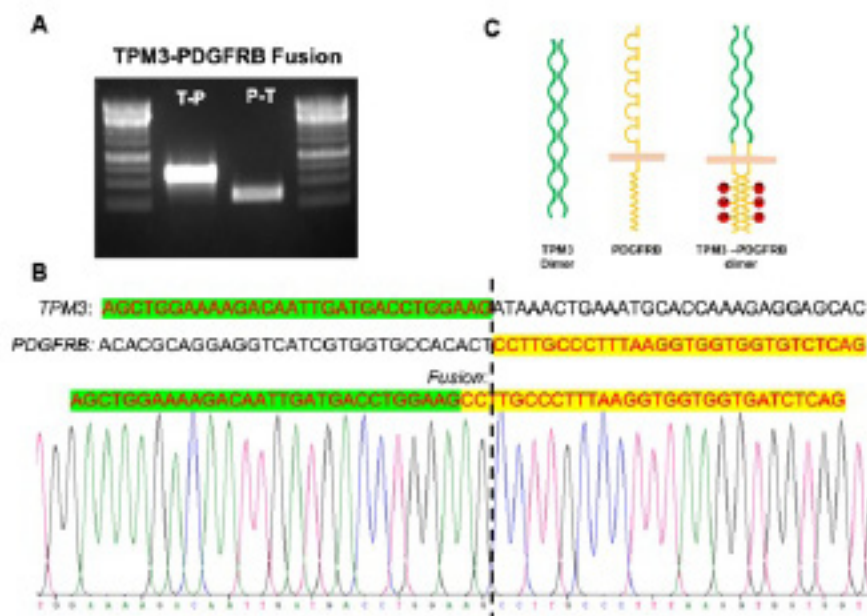
After ruling out the reactive causes of eosinophilia, the patient would be diagnosed as myeloid neoplasms associated with other rearrangement of PDGFRB according to the Revised 2016 World Health Organization Classification of Eosinophilic Disorders. And as diagnosis, the patient was treated with Hydrea and Imatinib. One-month Follow-up, all the symptoms have been alleviated. The CBC examination showed hemoglobin of 116g/L, a platelet count of  $82 \times 10^9/L$ , and a leukocyte count of  $8.57 \times 10^9/L$  with 0.1% of eosinophilic granulocyte. The B ultra-sound show a dramatic decrease of spleen size (58mm\*166mm\*16mm). Four-month follow-up visit, the patient had no symptoms and the examination showed a normal blood cell count.

While, interestingly in this case the rearrangement of PDGFRB gene is rarely seen in adult myeloid neoplasm with eosinophilia. Especially in this patient, t (1,5) (q21, q32), was formerly reported in only one CEL case with PDGFRB rearrangement, together with several hematological disorders [4]. As has been reported before, this chromosome translocation could result in one new fusion protein, TPM3-PDGFRB. Afterwards, we detect the fusion gene by PCR and sequencing. Interestingly, the fusion gene and the breakpoint was exactly the same as reported. The N-terminal of TPM3 possessed a dimerization domain, which could lead to the ligand independent activation of PDGFRB via fusing to PDGFRB gene

(Figure 2C). We also further confirmed the fusion gene of t(1,5) (q21,q32) according to the literature, as the identical translocation site. And as a consequence, the Polymerase Chain Reaction (PCR) amplification and sanger sequencing results confirmed the fusion gene was TPM3-PDGFRB (Figure 2A, B), indicating that the specific translocation could be a recurrent genetic event [4].

#### 4. Discussion

Myeloid/lymphoid neoplasms associated with eosinophilia and rearrangement of PDGFRA, PDGFRB, or FGFR1, or with PCM1-JAK2 were defined as subtypes of myeloid neoplasm according to the Revised 2016 World Health Organization (WHO) classification of myeloid neoplasms [5]. The clonal hyperplasia of eosinophilic granulocytes was the typical manifestation of this disease and the cause of multiple organ damages, which include skin, respiratory system, gastrointestinal, cardiac symptoms causing by eosinophil infiltration and release of granular content [6, 7]. Although the difference of the translocation of chromosomes, the consequences of PDGFRA/B translocations were nearly the same [8]. In the fusion oncogene, the partner gene always replaces the 5' end of PDGFRA/B. As a consequence, the expression of the oncogenic fusion product is controlled by the gene promoter of the partner gene [9]. So far, more than 32 and 8 genes were reported existing translocation with PDGFRB and PDGFRA, respectively [10].



**Figure 2:** PCR verification and sequence of the TPM3-PDGFRB fusion gene

(A) The amplification was performed with primers TPM3\_425F (AGGTGGCTCGTAAGTTGGTG) and PDGFRB\_2369R (TAGATGG-GTCCTCCTTTGGTG). The lanes showed the two fused gene product. (T-P, TPM3/PDGFRB, P-T, PDGFRB/TPM3) (B) the sequence of the cloned TPM3/PDGFRB (T-P) fusion. The dash line showed the breakpoint. (C) the function model of TPM3-PDGFRB fusion protein.

Referring to PDGFRB, more than 30 partners had been reported to generate fusion genes producing an activated tyrosine kinase that transforms hematopoietic cells due to constitutive activation [10]. PDGFR contained two receptors, which were PDGFR $\alpha$  and PDGFR $\beta$ , belonging to receptor tyrosine kinase. Physically it was activated by its ligand PDGF, and indirectly activated by dopamine, angiotensin II etc. through G-protein coupled receptor. Function study with PDGFRB knockout mice model detected severe deficient in vascular smooth muscle cells and the mice died soon after birth [11]. When genetic events happened, like the mutation or translocation, the dimer was locked to its activated form, regulating downstream SH2-domain-containing effectors. Thus, several signaling pathway, like PI3K-Akt pathway and MAPK pathway were upregulated and resulted in neoplastic proliferation [9, 12].

Although myeloid neoplasm with eosinophilia and rearrangement of PDGFRB was a single entity in the new WHO classification, PDGFRB alterations were rarely reported in hematological malignancies. In a study of 556 patients with myeloproliferative neoplasms, the incidence of PDGFRB rearrangement was 1.8% [13]. Also, in a single center study, the incidence of PDGFRB rearrangement in hyper eosinophilia patients was 9% (2/25) [14]. As been reported, the response rate of MPN with eosinophilia and PDGFRB rearrangement was more than 95% [3]. Thus, it was urgent to genetically diagnose the disease precisely.

TPM3 was an actin associating protein, participating in cell invasion and migration [15]. And also the mutated protein involved in clinical manifestation like muscle stiffness, which might also have related to the abnormally active interaction of the actin and myosin

complex [16]. The recent study also revealed that TPM3.1 could be necessary for the structural and functional maintenance of the axon initial segment [17]. The translocation of TPM3-ALK was also investigated in inflammatory myofibroblastic tumor, a mesenchymal tumor. The mechanism study demonstrated the coiled-coil structure of TPM3 contributed to the transforming ability of the TPM3-ALK fusion protein, and longer TPM3 region leads to higher dimer formation [18]. The TPM3 related hematological malignancy was also report before once in a chronic eosinophilic leukemia (CEL) patient [4].

In this case, we also verify the translocation pattern consist with which was reported once before in a patient with chronic eosinophilic leukemia [4]. While the translocations with TPM3 were quite rare in hematological diseases and the pathogenesis was usually closely related to its partner genes, the observation accumulation of the cases was needed to reveal the function of TPM3 in the disease.

## 5. Conclusion

Here we reported a case of myeloid neoplasm associated with eosinophilia and rearrangement of PDGFRB, of which we detected a rare translocation of t(1,5) (q21,q32) and a TPM3-PDGFRB fusion gene. The patient was clearly diagnosed and treated with Imatinib. The 1 year follow-up of the patient was normal with all the parameters. Since this kind of translocation is rare and sensitive to the tyrosine kinase inhibitor treatment, the early and precise diagnosis is necessary. As this could be the third reported case of the TPM3-PDGFRB translocation, more data should be accumulated to further reveal the pathogenesis of the fusion gene.

## 6. Disclosures

All authors state that they have no conflicts of interest.

## 7. Acknowledgments

The work was supported by the National Natural Science Foundation of China (81900799), the Science and Technology Commission of Shanghai Municipality (19YF1430400 and 19YF1429700), a grant from the Shanghai Municipal Health Bureau (20174Y0120), a grant from Guanci Foundation of Ruijin Hospital (GCQN-2018-B20), and a grant from the Young Investigator Development Foundation of Ruijin Hospital (KY20194219).

## Reference

1. Tefferi A, Patnaik MM and Pardanani A. Eosinophilia: secondary, clonal and idiopathic. *Br J Haematol.* 2006; 133(5): 468-492.
2. Shomali W and Gotlib J. World Health Organization-defined eosinophilic disorders: 2019 update on diagnosis, risk stratification, and management. *Am J Hematol.* 2019; 94(10): 1149-1167.
3. Cheah CY, Burbury K, Apperley JF, Huguet F, Pitini V, Gardembas M, et al. Patients with myeloid malignancies bearing PDGFRB fusion genes achieve durable long-term remissions with imatinib. *Blood.* 2014; 123(23): 3574-3577.
4. Rosati R, La Starza R, Luciano L, Gorello P, Matteucci C, et al. TPM3/PDGFRB fusion transcript and its reciprocal in chronic eosinophilic leukemia. *Leukemia.* 2006; 20(9): 1623-1624.
5. Gotlib J. World Health Organization-defined eosinophilic disorders: 2017 update on diagnosis, risk stratification, and management. *Am J Hematol.* 2017; 92(11): 1243-1259.
6. Maric I and Sun X. Advances in diagnosis of mastocytosis and hypereosinophilic syndrome\*. *Semin Hematol.* 2019; 56(1): 22-29.
7. Wang SA. The Diagnostic Work-Up of Hypereosinophilia. *Pathobiology.* 2019; 86(1): 39-52.
8. Demoulin JB and Montano-Almendras CP. Platelet-derived growth factors and their receptors in normal and malignant hematopoiesis. *Am J Blood Res.* 2012; 2(1): 44-56.
9. Demoulin JB and Essaghir A. PDGF receptor signaling networks in normal and cancer cells. *Cytokine Growth Factor Rev.* 2014; 25(3): 273-283.
10. Reiter A and Gotlib J. Myeloid neoplasms with eosinophilia. *Blood.* 2017; 129(6): 704-714.
11. Lindahl P, Johansson BR, Leveen P and Betsholtz C. Pericyte loss and microaneurysm formation in PDGF-B-deficient mice. *Science.* 1997; 277(5323): 242-245.
12. Papadopoulos N and Lennartsson J. The PDGF/PDGFR pathway as a drug target. *Mol Aspects Med.* 2018; 62: 75-88.
13. Arefi M, Garcia JL, Penarrubia MJ, Queizan JA, Hermosin L, López-Corral L, et al. Incidence and clinical characteristics of myeloproliferative neoplasms displaying a PDGFRB rearrangement. *Eur J Haematol.* 2012; 89(1): 37-41.
14. Hu Z, Boddu PC, Loghavi S, Miranda RN, Goswami M, Medeiros LJ, et al. A multimodality work-up of patients with Hypereosinophilia. *Am J Hematol.* 2018; 93(11): 1337-1346.
15. Gunning PW and Hardeman EC. Tropomyosins. *Curr Biol.* 2017; 27(1): R8-R13.
16. Donkervoort S, Papadaki M, de Winter JM, Neu MB, Kirschner J, Bolduc V, et al. TPM3 deletions cause a hypercontractile congenital muscle stiffness phenotype. *Ann Neurol.* 2015; 78(6): 982-994.
17. Abouelezz A, Stefen H, Segerstrale M, Micinski D, Minkeviciene R, Lahti L, et al. Tropomyosin Tpm3.1 Is Required to Maintain the Structure and Function of the Axon Initial Segment. *iScience.* 2020; 23(5): 101053.
18. Amano Y, Ishikawa R, Sakatani T, Ichinose J, Sunohara M, Watanabe K, et al. Oncogenic TPM3-ALK activation requires dimerization through the coiled-coil structure of TPM3. *Biochem Biophys Res Commun.* 2015; 457(3): 457-460.