

Forearm Cutaneous Metastasis of Rectal Adenocarcinoma: A Case Report

Fiore G^{1#}, Caramia T^{1#}, Pagliuca F², Farinaro A¹, Maddalena C¹, Camardella S¹, De Placido S¹, Franco R² and Carlomagno C^{1*}

¹Department of Clinical Medicine and Surgery, University of Naples "Federico II", Naples, Italy

²Pathology Unit, Department of Mental and Physical Health and Preventive Medicine, University of Campania "Luigi Vanvitelli", Naples, Italy

Volume 4 Issue 7- 2020

Received Date: 20 July 2020

Accepted Date: 30 July 2020

Published Date: 04 Aug 2020

2. Key words

Cutaneous metastasis; Metastatic colorectal adenocarcinoma; Colorectal cancer; Skin metastasis; Forearm;

1. Abstract

Cutaneous metastases are a rare entity and those resulting from metastatic colorectal cancer account for 4-6,5% of cases. Many mechanism for cutaneous metastases have been hypothesized. They could occur through lymphatic and hematogenous spread, direct extension of tumor and for surgical implantation. We report the story of a 56-years-old woman who developed a skin metastasis in an unusual site, the dorsal surface of the right forearm, 5 years after diagnosis of a rectal adenocarcinoma. The lesion was radically excised and the histopathological examination showed an adenocarcinoma compatible with rectal origin, positive for cytokeratin 20 and CDX2. Systemic chemotherapy has being administered due to lung and bone metastases.

3. Introduction

Cutaneous metastases are rare in internal-organs malignancies, and most of the data about their incidence derives from retrospective series of post-mortem examinations. Lookingbill et al. reported an overall incidence of 9.6% in patients affected by metastatic tumors excluding melanoma [1], and 10.4% including melanoma [2]. In a small percentage of cases (7.6%) skin metastases represent the first sign of extra-nodal disease, mostly (78%) without visceral involvement. Solid tumors that metastasize most frequently to the skin are melanoma, breast cancer and upper respiratory tract, while skin secondary lesions from colorectal cancers are uncommon. Cutaneous metastasis are mainly located on chest, back, abdomen, scalp and lower extremities [2], those originated from colorectal cancer (4-6.5% of patients) are mainly on the abdominal wall [3], rarely on the trunk, scrotum [2, 4, 5], penis [6] and face [7].

We present the story of a patient who developed a skin metastasis in an unusual site, the dorsal surface of the right forearm, 5 years after diagnosis of a rectal adenocarcinoma.

4. Case report

A 50-year-old caucasian female in November 2014, was referred to our Institution by the family doctor for constipation, rectal pain and red blood in stool. The colonoscopy showed a suspicious lesion, 13 cm from the anal margin and the histopathological analysis of the biopsy revealed a moderately differentiated adenocarcinoma.

The whole body Computer Tomography (CT) scan and the pelvic magnetic resonance imaging (MRI) showed a rectal mass confined within the rectal wall (cT2), the presence of abnormal perirectal lymph nodes (cN+) without distant metastases (cM0). The patients received neoadjuvant treatment with concomitant capecitabine and radiotherapy (45 Gy plus rectal boost, 5.4 Gy in total). After two months from the end of chemoradiation, the re-staging whole body CT scan and the pelvic RMI showed a reduction of the rectal mass and of the number of mesorectal lymph nodes. On April 2015, the patient underwent radical surgery (low anterior resection of the rectum following the Total Mesorectal Excision technique). The histopathological examination showed the persistence of well differentiated adenocarcinoma in the rectal wall, and in 3 out of 18 perirectal lymph nodes and in 1 precaval lymph node (TNM staging was ypT3N1M1), Mandard Tumor Regression Grade 4, mutation in exon 12 of the KRAS gene. The surgical intervention was considered R0. The patient received 6 months of adjuvant chemotherapy with fluoropyrimidines and oxaliplatin, and subsequently underwent periodical follow-up. In March 2016, the whole body CT scan showed two metastatic nodules (Ø 6 mm in the lower lobe of the right lung and Ø 5 mm in the lower lobe of the left lung). Due to the short interval from the end of the adjuvant chemotherapy (about 6 months) and the small size of the lung nodules, stereotactic radiotherapy was delivered (39 Gy to each of the two lung nodules). After about one progression-free year, on May 2017 a

#Author Contributions: Caramia T, Fiore G. These authors have contributed equally to this article.

Citation: Fiore G. Forearm Cutaneous Metastasis of Rectal Adenocarcinoma: A Case Report. Annals of Clinical and Medical Case Reports. 2020; 4(7): 1-3.

*Corresponding Author (s): Chiara Carlomagno, Department of Clinical Medicine and Surgery, University of Naples "Federico II", Via Sergio Pansini 5 80131 Naples, Italy, Tel: +39 081 7464271, E-mail: ccarloma@unina.it

CT scan showed a novel metastatic nodule in the lower lobe of the right lung, which was treated with additional stereotactic radiotherapy (45 Gy). In September 2017, a further disease progression was registered with the appearance of an osteolytic metastasis at the distal right humerus. Radiation therapy (39 Gy) was delivered and treatment with denosumab, oral calcium and cholecalciferol was started. In July 2018 a further disease progression occurred (dimensional increase of two known lung nodules and novel lung ones appearance) and the patient started first-line chemotherapy with FOLFIRI (5-fluorouracil, folinic acid and irinotecan) plus bevacizumab (12 induction cycles) followed by maintenance with HD-FUFA (De Gramont 5fluorouracil/folinic acid schedule) + bevacizumab for further 10 cycles. The best response was a stable disease (SD) registered after the 6th cycle. In September 2019 all the lung metastases showed a dimensional increase; the patient refused intravenous chemotherapy, therefore received second-line Regorafenib for 6 cycles, obtaining a stabilization as best response. In February 2020 a 10 x 8 mm pink nodular skin lesion with central erosion and topped with squamous crust at the dorsal surface of the right forearm was observed (Figure 1). The lesion was radically excised and the histopathological examination confirmed the diagnosis of a well-differentiated adenocarcinoma of rectal origin, positive for cytokeratin 20 and CDX2 (Figures 2-3). In March 2020, due to the skin metastasis, the appearance of lymph-nodes in right axilla and the further progression of the lung nodules, a third-line treatment with the FOLFOX (5-fluorouracil, folinic acid and oxaliplatin) plus Bevacizumab regimen was started (still ongoing); the response after 6 cycles was a stable disease.

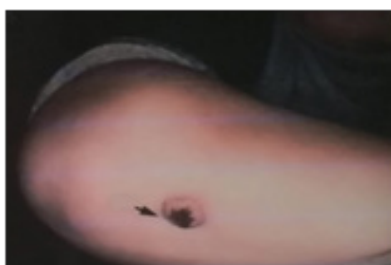


Figure 1: Clinical photograph of the dorsal surface of the right forearm showing well-defined, firm, pink nodular skin lesion with central erosion and topped with squamous crust (black arrow).

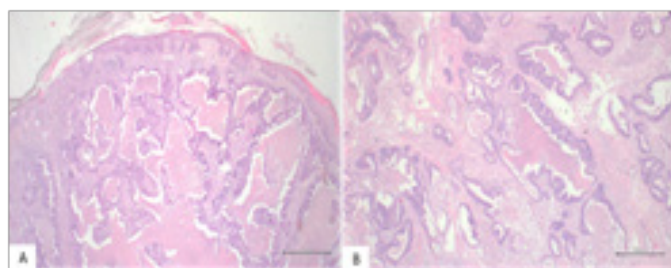


Figure 2: Colonic adenocarcinoma metastatic to skin: histological findings. (A) Low-power view shows an adenocarcinoma with widespread dermal infiltration. (Hematoxylin and Eosin stain; original magnification: 20x); (B) the tumor is characterized by glandular differentiation and intraluminal necrotic debris ('dirty' necrosis). (Hematoxylin and Eosin stain; original magnification: 40x).

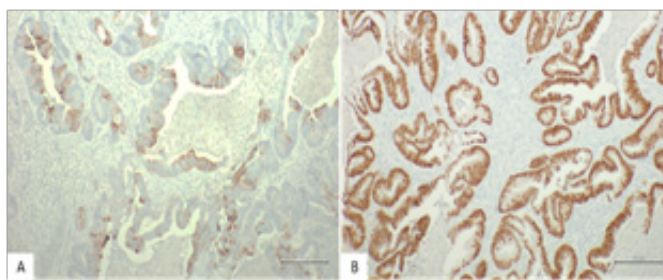


Figure 3: Colonic adenocarcinoma metastatic to skin: immunohistochemical findings.

(A) Tumor cells are focally positive for cytokeratin 20. Cytokeratin 20 expression combined with absence of cytokeratin 7 favors an origin from the intestinal tract. (Cytokeratin 20 immunostain; original magnification: 100x); (B) Tumor cells show strong and diffuse nuclear staining for CDX2. CDX2, a homeobox gene encoding for an intestinal epithelial transcription factors, is considered a highly specific markers for gastrointestinal tract origin. (CDX2 immunostain; original magnification: 100x).

5. Discussion

Cutaneous metastases generally occur in the later phase of metastatic malignancies, and, at least in colorectal cancer patients, are rarely isolated, and often simultaneous to other parenchymal metastases [3, 8]. Cutaneous spread is rarely the first metastatic site; in a small series of cases the appearance of skin involvement varies from the time of primary tumour diagnosis to many years after primary surgical removal [3]. In our patient the skin metastasis occurred 5 years after the diagnosis of colon cancer and about four years after the first lung metastases. Many mechanism for cutaneous metastases have been hypothesized. They could occur through lymphatic and hematogenous spread, direct extension of tumor and surgical implantation [9]. In our patient, it is unlikely that spread to the skin of the dorsal surface of the right forearm occurred via direct extension from humeral metastasis because the deep margin of the skin nodule excision was free from adenocarcinoma. Cutaneous metastases could occur in a variety of clinical manifestations, sometimes mimicking cellulitis, epidermal cysts, lipomas or zona zoster, other times they might be nodules, bullae, ulceration and fibrotic processes. Skin metastases due to colorectal cancers have no peculiar features, presenting often as small dermal or subcutaneous nodules, which can measure 10-20 mm in diameter and they are generally asymptomatic and painless [2, 7]. In this case it was a 10 mm in diameter pink nodular skin lesion with central erosion and topped with squamous crust at the dorsal surface of the right forearm, that was radically excised, with clear lateral and deep margins. The mass involved subcutaneous tissue plan, but not the deeper muscles. Important histological clues favouring a cutaneous metastasis over a primitive tumor include multifocality, primary dermal location and the presence of extensive lymphovascular invasion. However, none of these criteria can be considered entirely specific and careful clinical-pathological correlation remains fundamental to pose the correct diagnosis. In this context, immunohistochemistry is of invaluable help to provide a

molecular characterization of the tumor, demonstrating its origin [10]. With reference to metastatic colorectal carcinoma, histological features suggesting an intestinal origin include glandular differentiation (utterly non-specific per se) of mucin-producing cells combined with the presence of intraluminal necrotic debris, the so-called 'dirty necrosis'. Useful immunohistochemical markers are cytokeratin 20 and CDX2 [11-13]. Cytokeratin 20 is a low molecular weight cytokeratin mostly expressed in the lower gastrointestinal tract while CDX2, an intestinal epithelial transcription factor, is considered a highly specific marker for gastrointestinal tract origin. In the current case, the typical histomorphological features of glandular architecture and dirty necrosis, the dermal location with lymph vascular invasion together with the immunohistochemical results led to the diagnosis of cutaneous metastasis from primary colorectal adenocarcinoma. There is no standard of therapy for cutaneous metastasis by colorectal primary tumour. For an isolated lesion, with or without visceral metastases, a wide local excision and reconstruction, such as in our patient, could be proposed [7] or local palliative radiotherapy because of pain too [14]. Skin metastases rarely occur without parenchymal ones; consequently, a systemic chemotherapy represents the first therapeutic option to consider [7].

6. Conclusions

Cutaneous metastases are a rare event, but they have to be recognized, as they are often sign of distant dissemination and poor prognosis. Any cutaneous lesion in a patient affected by metastatic colorectal cancer requires careful dermatological examination [15], and a skin metastasis have to be suspected. Early detection and optimal management are important to prevent the development of disease dissemination and to ensure a longer life expectancy, especially when the cutaneous localization is not associated with visceral metastases.

References

1. Lookingbill DP, Spangler N, Sexton FM. Skin involvement as the presenting sign of internal carcinoma. A retrospective study of 7316 cancer patients. *J Am Acad Dermatol.* 1990; 22(1): 19-26.
2. Lookingbill DP, Spangler N, Helm KF. Cutaneous metastases in patients with metastatic carcinoma: a retrospective study of 4020 patients. *J Am Acad Dermatol.* 1993; 29(2 Pt 1): 228-36.
3. Saeed S, Keehn CA, Morgan MB. Cutaneous metastasis: a clinical, pathological, and immunohistochemical appraisal. *J Cutan Pathol.* 2004; 31(6): 419-30.
4. Malla S, Razik A, Vyas S. Cutaneous metastasis in adenocarcinoma rectum. *BMJ Case Rep.* 2019; 12(4): e229652.
5. Udkoff J, Cohen PR. Adenocarcinoma of the colon presenting with scrotal metastasis: case report and review of the literature. *Dermatol Online J.* 2016; 22(1): 13030.
6. Ahmad SW, Daze RP, Arvaneh S, Awad S. Painful Penile Plaques: A

Rare Case Report of Rectal Adenocarcinoma with Cutaneous Metastasis to the Penis. *Cureus.* 2019; 11(7): e5095.

7. Hashimi Y, Dholakia S. Facial cutaneous metastasis of colorectal adenocarcinoma. *BMJ Case Rep.* 2013.
8. Nesseris I, Tsamakis C, Gregoriou S, Ditsos I, Christofidou E, Rigopoulos D. Cutaneous metastasis of colon adenocarcinoma: case report and review of the literature. *An Bras Dermatol.* 2013; 88(6): 56-8.
9. Kauffman CL, Sina B. Metastatic inflammatory carcinoma of the rectum: tumor spread by three routes. *Am J Dermatopathol.* 1997; 19(5): 528-32.
10. Wong CY, Helm MA, Kalb RE, Helm TN, Zeitouni NC. The presentation, pathology, and current management strategies of cutaneous metastasis. *N Am J Med Sci.* 2013; 5(9): 499-504.
11. Liao XY, Liu CY, Liang LB, Du JR, Zhang T. Cutaneous and breast metastasis from colorectal adenocarcinoma: A rare case report. *Mol Clin Oncol.* 2019; 11(2): 143-6.
12. Faenza M, Del Torto G, Di Costanzo P, et al. Large single cutaneous metastasis of colon adenocarcinoma mimicking a squamous cell carcinoma of the skin: A case report. *Int J Surg Case Rep.* 2019; 56: 96-100.
13. Habermehl G, Ko J. Cutaneous Metastases: A Review and Diagnostic Approach to Tumors of Unknown Origin. *Arch Pathol Lab Med.* 2019; 143(8): 943-57.
14. Kemal Y, Odabaşı EA, Kemal Ö, Bakırtaş M. Cutaneous metastasis of colon adenocarcinoma. *Turk J Surg.* 2018; 34(3): 237-9.
15. Dehal A, Patel S, Kim S, Shapera E, Hussain F. Cutaneous Metastasis of Rectal Cancer: A Case Report and Literature Review. *Perm J.* 2016; 20(1): 74-8.