

Colopleural Fistula. A Case Report and Review of Literature

Quiroz-Guadarrama CD¹, Luna-Guerrero CE², Lopez-Rico LA² and Vargas-Flores E^{3,*}

¹Hospital General de Zona 2. IMSS. Hermosillo, Sonora

²Hospital General de Zona 5. IMSS. Hermosillo, Sonora

³Hospital General Dr. Manuel Gea González. Mexico City

Volume 3 Issue 5- 2020

Received Date: 24 Apr 2020

Accepted Date: 04 May 2020

Published Date: 07 May 2020

2. Key Words:

Colopleural Fistula; Colonic Fistula;
Fistula

1. Abstract

The presence of a colopleural fistula is a rare event related to several factors, inadequate placement of drains, poor surgical technique, infection or dehiscence of a GI anastomosis. Only a small percentage occurs as a complication of inflammatory bowel disease, cancer, trauma or radiation.

We report the case of a young male patient presenting with a colopleural fistula associated with penetrating abdominal trauma and multiple surgical interventions.

The principles in the management of gastrointestinal fistulas (resuscitation, biochemical workup, definitive treatment, and rehabilitation), continue to be valid as a standard on the medical and surgical decision-making protocol of this clinical problem.

3. Introduction

Gastrointestinal fistulas represent abnormal communication between two epithelized surfaces, they generally receive their name according to their anatomical components and the manifestations depend on the affected structures.

A fistula formation affects the clinical evolution and outcomes of the patient, due in large part to sepsis and malnutrition, resulting in a clinical decline of the quality of life in the psychological, social and occupational aspects [1].

Approximately 80% of gastrointestinal fistulas occur as a surgical complication of recent abdominal surgery, caused by a wide variety of factors, including inappropriate surgical technique, inadequate placement of drains, infectious process, and dehiscence of the anastomosis. However, in a lower percentage, they are a not uncommon manifestation of the progression of inflammatory bowel disease, cancer, and radiotherapy [2].

We present the case of a male patient in the second decade of life with a colopleural fistula associated with penetrating abdominal trauma and multiple surgical reoperations secondary to abdominal sepsis. We analyze the main risk factors, clinical presentation as well as the medical and surgical approach.

4. Case Report

A 17-year-old patient is referred to our surgical clinic with a diagnosis of enterocutaneous fistula. His past medical history reveals a history of penetrating abdominal gunshot trauma, multiple abdominal surgical interventions due to abdominal sepsis, and the diagnosis of enterocutaneous fistula. A CT scan of the thorax showed a left pleural effusion (Figure 1). He required ICU management for 30 days. Upon his arrival at our clinic, the patient was on an open abdomen with a tube thoracostomy draining purulent material. Clinical and biochemical signs of severe sepsis were present. Upon his arrival, initial management included aggressive intravenous fluid resuscitation and imaging studies showed the presence of a left colopleural fistula (Figure 2) and a colonoscopy later showed the presence of a communication between the colon and the pleural space (Figure 3). Conservative treatment was started, including total parenteral nutrition, intravenous hydration, and antibiotics. The patient later presented clinical signs of intestinal obstruction which required an exploratory laparotomy with a transverse colostomy, thoracotomy, and left hemithorax decortication. He had an uneventful surgical evolution that resulted in discharge from the hospital after the clinical resolution of the above mentioned medical problems.

*Corresponding Author (s): Edgar Vargas-Flores, Hospital General Dr. Manuel Gea González. Tlalpan 14000. Mexico city, Mexico, E-mail: eddgar868@gmail.com

Citation: Vargas-Flores E, Colopleural Fistula. A Case Report and Review of Literature. Annals of Clinical and Medical Case Reports. 2020; 3(5): 1-3.

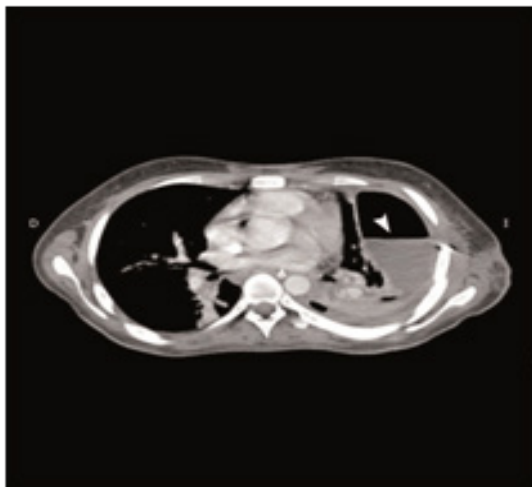


Figure 1: Contrast thoracic CT scan showing a left pleural effusion (white arrow).

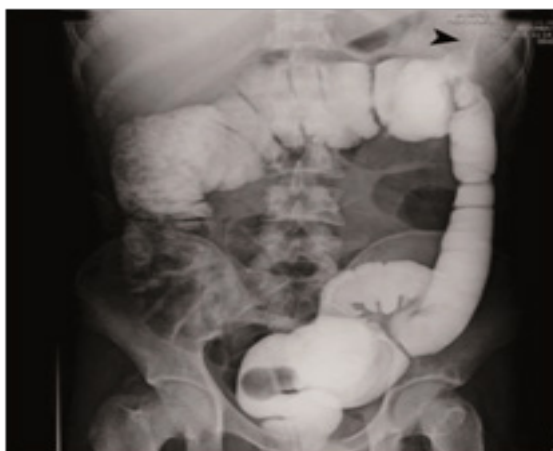

Figure 2: Contrast barium enema showing communication between colon and pleural cavity (black arrow).

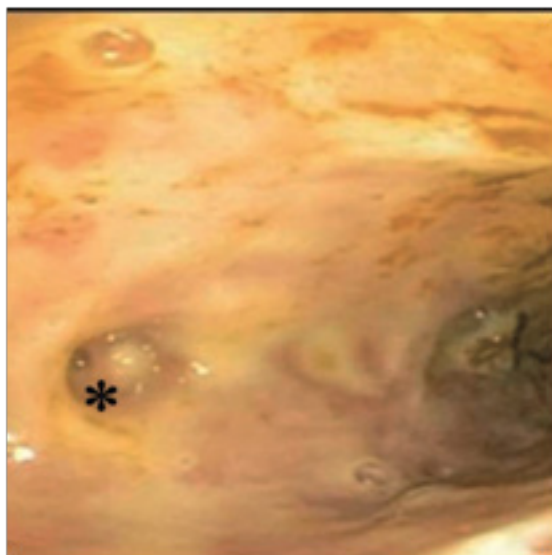


Figure 3: Colonoscopy showing a small orifice in the colon (asterisk) communicating with the left pleural cavity.

5. DISCUSSION

Regarding pleural pathology, both pneumothorax and pleural effusion are quite frequent in the thoracic surgery and general surgery services. Parapneumonic or metapneumonic empyema or empyema secondary to digestive processes are the most frequent entity within infectious pleural pathology, however, we must take into account rare entities that can proceed slowly and be potentially be more serious [3].

Haleem et al. 2005 reviewed the main risk factors and clinical manifestations associated with colopleural fistula; They found that this type of fistula is caused secondary to trauma, malignant pathology (neoplasm of the gastrointestinal tract) or benign pathology such as Crohn's disease or diverticulitis [4].

Typically, it presents with hydropneumothorax without associated abdominal symptoms. The traumatic form, being the most frequent within them, it's associated with diaphragmatic rupture and herniation of the abdominal content into the pleural space. late presentations may appear months or years later after the initial trauma [5].

A low incidence of traumatic colopleural fistulae has been reported in the literature. The first report corresponds to Radin rd et al. Reported the case of a 35-year-old patient who, after 5 years of being treated for a stab wound to the chest, presented with hydropneumothorax caused by herniation and perforation of the transverse colon into the thoracic cavity [6].

Lacayo et al. Reported the case of a 20-year-old woman who presented with respiratory distress 4 hours after a cesarean section delivery. The radiograph showed pleural effusion and a tension pneumothorax. later on, the insertion of a thoracic drainage tube revealed liquid stool. Her past medical history was relevant for a penetrating stab wound in the left hemithorax two years before admission [7].

Seeling et al. Reported a patient who, after two years of being treated for a gunshot injury, presented with an acute tension pneumothorax caused by colonic entrapment and perforation into the thoracic cavity [8].

Barisiae, et al. Presented the case of a 25-year-old patient with a history of Crohn's disease, who presented with dyspnea, fever, and abdominal pain. On physical examination, there were decreased breath sounds on the left hemithorax. Chest x rays revealed a left pleural effusion. Tube thoracostomy showed fecal drainage and a barium enema with the presence of a fistula at the level of the splenic angle towards the left hemithorax [9].

In 1989 Sinha et al 1989 reported the case of a 50-year-old patient, who presented with a tension pneumothorax, an endopleural tube was placed, draining fecal material. It was decided to perform an exploratory laparotomy finding a strangulated Bochdalek hernia. He had a history of intermittent abdominal pain, pain in the right hemithorax, and respiratory distress of a couple of weeks of evolution [10].

Haleem and Khan in 2008 reported the case of a 28-year-old and a 24 weeks of gestation pregnant woman, who presented with a 3-day onset acute right chest pain and respiratory distress. Past medical history revealed a right partial hepatic lobectomy and open cholecystectomy 2 years before presentation. Chest x rays revealed a right pleural effusion. A thoracic CT scan was performed, observing a right colo-pleural communication [4].

Papagiannopoulos, et al. reported the case of a 46-year-old patient who underwent surgery for a perforated colonic diverticulum complicated by an abscess. Two months later, he presented with complaints of fever, abdominal pain in the left upper quadrant and left hemithorax accompanied by weight loss. A thoracoabdominal CT scan showed colopleural communication [5].

Radin et al. Reported the case of a patient who, after 4 years of being treated for a stab wound in the left hemithorax, presented with tension pneumothorax, secondary to a strangulated diaphragmatic hernia [6].

The aforementioned cases, like our patient, showed signs of hydrothorax and drainage of fecaloid material through the pleural tube. The presentation of the colopleural fistula in the cases reported in the literature was late, (2-5 weeks after the initial trauma) however, our patient developed the fistula earlier. Surgical treatment in all three depicted cases was on an urgent basis, with thoracotomy, decortication, and thoracic drainage being performed. A colectomy of the compromised segment and a proximal colostomy was performed, however, we opted for a more conservative management, performing thoracotomy, decortication, and chest drainage (with decreasing fistula output), control of sepsis, and significant clinical improvement. However, after 6 weeks of medical management, he presented intestinal obstruction, requiring urgent surgery, performing a diaphragmatic myoplasty, a transverse colectomy, proximal colostomy, and a distal closure.

6. Conclusion

The presence of a colopleural fistula is a rare entity and is seldom reported in the medical literature. The principles in the management of gastrointestinal fistulas (resuscitation, biochemical work-up, definitive treatment, and rehabilitation), continue to be valid as

a standard on the medical and surgical decision-making protocol of this clinical problem.

References

1. Pickhardt PJ, Bhalla S, Balfé DM. Acquired gastrointestinal fistulas: Classification, etiologies, and imaging evaluation. *Radiology*. 2002; 224: 9-2.
2. Hwan KS, Hyeong OJ, Jung KH. Interventional management of gastrointestinal fistulas. *Korean J Radiol*. 2008; 9: 541-9.
3. Reddy SA, Vemuru R, Padmanabhan K, Steinheber FU. Colopleural fistula presenting as tension pneumothorax in strangulated diaphragmatic hernia: Report of a case. *Dis Colon Rectum*. 1989; 32: 165-8.
4. Haleem AA, Khan FY, Almuzrahshi AM, Zeer HE, Rasul FA. Colopleural fistula: Case report and review of the literature. *Annals of Thoracic Medicine*. 2007; 3: 122-4.
5. Papagiannopoulos K, Gialvalis D, Dodo I, Darby MJ. Empyema resulting from a true colopleural fistula complicating a perforated sigmoid diverticulum. *Ann Thorac Surg*. 2004; 77: 324-6.
6. Radin DR, Ray MJ, Halls JM. Strangulated diaphragmatic hernia with pneumothorax due to colopleural fistula. *AJR Am J Roentgenol*. 1986; 146: 321-2.
7. Lacayo L, Taveras JM, Sosa N, Ratzan KR. Tension fecal pneumothorax in a postpartum patient. *Chest*. 1993; 103: 950-1.
8. Seelig MH, Klingler PJ, Schonleben K. Tension fecopneumothorax due to colonic perforation in a diaphragmatic hernia. *Chest*. 1999; 115: 288-91.
9. Barišić G, Krivokapić Z, Adžić T, Pavlović A, Popović M, Gojnić M. Fecopneumothorax and colopleural fistula – uncommon complications of Crohn's disease. *BMC Gastroenterology* 2006;6
10. Sinha M, Gibbons P, Kennedy SC, Matthews HR. Colopleural fistula due to strangulated Bochdalek hernia in an adult. *Thorax* 1989; 44: 762-3.