

MRI-Guided Stereotactic Craniotomy to Set the Diagnosis of CNS Cryptococcosis. Case Report and Review of the International Literature

Papadopoulos EK¹, Solou M^{1*}, Gavra M², Ydreos J¹ and Boviatsis EJ¹

¹Department of Neurosurgery, "Attikon" University General Hospital, National and Kapodistrian University, Athens Medical School, Chaidari, Greece

²Department of CT and MRI Imaging, "Agia Sofia" Children's Hospital, Athens, Greece

*Corresponding author:

Mary Solou,
Department of Neurosurgery and
Neurotraumatology, "Attikon" University General
Hospital, Rimini, 12462, Chaidari, Attiki, Greece,
Tel: +302105831525;
E-mail: marysolou06@gmail.com

Received: 15 Oct 2022

Accepted: 25 Oct 2022

Published: 31 Oct 2022

J Short Name: ACMCR

Copyright:

©2022 Solou M. This is an open access article distributed under the terms of the Creative Commons Attribution License, which permits unrestricted use, distribution, and build upon your work non-commercially

Citation:

Solou M, MRI-Guided Stereotactic Craniotomy to Set the Diagnosis of CNS Cryptococcosis. Case Report and Review of the International Literature. Ann Clin Med Case Rep. 2022; V10(3): 1-3

Keywords:

Cryptococcus; Encephalitis; Stereotactic craniotomy

1. Abstract

Cryptococcosis - a fungal infection - mainly caused by *Cryptococcus Neoformans* and *Cryptococcus Gattii*, may affect human central neural system (CNS) with various clinical manifestations. Diagnosis is usually confirmed by direct CSF microscopic examination for encapsulated yeasts by India ink preparation. However, sometimes laboratory tests may not be indicative and brain imaging with biopsy is necessary to reveal the cause in order to offer the adequate beneficial treatment to patients. We present a case of Cryptococcosis diagnosed by our department while reviewing the international literature.

2. Introduction

Cryptococcosis is considered an invasive fungal infection that is caused by *Cryptococcus* species. Although no human-to-human transmission has been observed, recently cryptococci have been identified to infect and potentially eliminate their human hosts [1,2]. Currently there are two species that commonly cause disease in humans, *C.Neoformans* and *C.Gattii*, mainly affecting immunocompromised patients or patients with pre-existing medical conditions [3].

The aim of this article is to present a case of cryptococcosis diagnosed by our department while reviewing the international literature.

3. Materials and Methods

A previously healthy 44 year old female patient presented with an episode of sudden loss of consciousness. No previous medical history has been reported, including no history of recurrent infections, no travel history outside the state, and was not taking any medications before her admission to the hospital. Her family was healthy. The episode was repeated for additional three times within the first 24 hours from the onset of the symptoms. Patient was admitted in the hospital and the initial assessment correlated the episodes with generalized tonic-clonic seizures. The seizures were associated with postictus urinary loss. On the fifth day of the hospitalization the patient mild temperature elevation (37,5 °C) was added to the symptoms.

The initial neurological assessment did not revealed any significant deficit with the exception of increased right side reflexes. The cognitive evaluation, the cranial nerve function, the motor function and the cerebellar tests were within normal range.

The laboratory analysis, including biochemical results were normal (Table 1), while the infection laboratory panel tests were negative as well (Table 2).

The patient underwent a brain imaging testing. The CT scan that revealed a minor non-enhancing hypodense lesion on the left temporal area, with associated perifocal edema (Figure 1). In addition to that the head MRI showed a focal lesion of the left temporal

lobe with low signal on T1-weighted sequence and high signal on T2-weighted sequence (Figure 2). The differential diagnosis of the lesion presented in the brain imaging included metastasis and brain abscess.

Patient underwent a CT-guided stereotactic minor craniotomy and removal of the lesion of the left temporal lobe within normal margins. The postoperative recovery of the patient was uneventful.

Table 1: Laboratory tests

Laboratory tests:	Results:
Hct	37,3%
WBC (Neu:80%)	6190
PLT	306000
Erythrocyte Sedimentation Rate (ESR)	10mm/hour
Sodium	138,2mmol/L
Potassium	3,98mmol/L
BUN	23mg/dL
Serum Creatinine	0,7mg/dL
GGT	19
SGOT	16
SGPT	14

Table 2: Inflammatory biomarkers

Inflammatory biomarkers:	Results:
CRP	(-)
Widal	(-)
Wright	(-)
Borrelia	(-)
ASTO	(-)
Toxo-IgM	(-)
Toxo-IgG	(-)
ANA	(-)
HIV	(-)

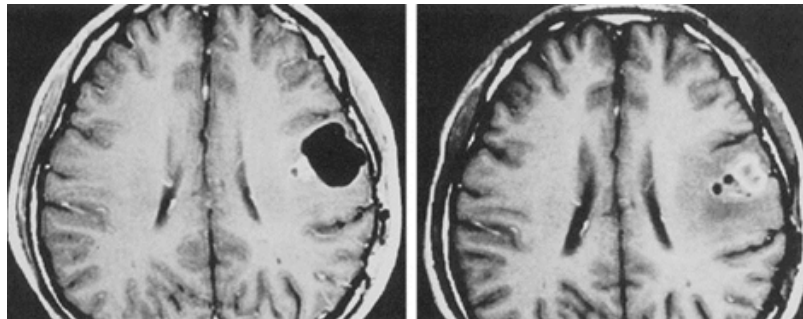


Figure 1: CT-brain

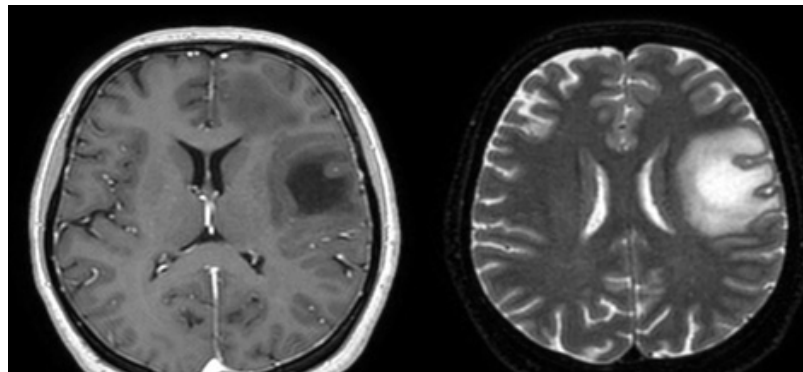


Figure 2: MRI brain (T1-weighted, T2-weighted)

4. Results

Pathology on the surgical specimen revealed 3 minor tissue samples, of various sizes ranging from 6mm to 10mm. Microscopic analysis revealed brain grey matter with parts of granulomatous necrotic inflammation, while *Cryptococcus* fungi were observed within the specimen. The conclusive result of pathology report was *Cryptococcus* encephalitis. Patient was referred to Infectious Disease Department for further treatment and was eventually discharged home after the adequate treatment.

5. Discussion

The majority of *Cryptococcus* infections in humans are caused by *C. Neoformans* (99%), while the minor remaining 1% is caused by the *C. Gattii* species [4,5], with endemic variety in Australia and New Zealand [3,6]. CNS clinical manifestations vary and might range from headache, increased temperature, seizures, loss or altered level of consciousness, neurological deficits from cranial nerves and upper or lower extremities and signs of meningitis [3,7–9]. The time interval from the onset of the infection until the development of the clinical manifestations usually includes several weeks, whereas there cases with sudden onset, and lack of symptoms and signs have been reported as well [10]. The diagnosis is usually based on direct CSF microscopic examination for encapsulated yeasts by India ink preparation. Histopathology in cases of severe CNS infection includes substantial thickening of meninges, diffuse infiltration of *Cryptococci* spp in the parenchyma, and associated inflammation and oedema [11]. The brain imaging testing in our case, including brain CT and MRI were consistent with the findings reported in the international literature including the low-density on T1-weighted and high-density lesions on T2-weighted MRI images of the cryptococcomas [12,13]. While the majority of the cases are being diagnosed by blood and CSF laboratory analysis, in our case that the initial results were within normal range, and there was a high indication of CNS infection from the brain MRI findings, the diagnosis was set by surgically removal of the lesion and subsequent histopathology [14,15].

6. Conclusion

Cryptococcosis is a worldwide high recognizable opportunistic fungal infection that may disseminate to the CNS causing meningoencephalitis with possible fatal consequences. Primary diagnosis elaborates the adequate beneficial treatment of the disease that is required for satisfactory outcome. Although the diagnosis is usually set by laboratory blood and CSF test, when these do not prove to be conclusive and the brain imaging testing indicate the possibility of a surgically removable lesion, a navigated craniotomy and removal of the lesion should be performed and the subsequent histopathological examination could possibly establish the diagnosis of *Cryptococcus* CNS infection.

References

1. May RC, Stone NRH, Wiesner DL, Bicanic T, Nielsen K. *Cryptococcus*: from environmental saprophyte to global pathogen. *Nat Rev Microbiol*. 2016; 14: 106–17.
2. Bartlett KH, Cheng P-Y, Duncan C, Galanis E, Hoang L, Kidd S, et al. A decade of experience: *Cryptococcus gattii* in British Columbia. *Mycopathologia*. 2012; 173: 311–9.
3. Maziarz EK, Perfect JR. Cryptococcosis. *Infect Dis Clin North Am*. 2016; 30: 179-206.
4. Harris JR, Lockhart SR, Debess E, Marsden-Haug N, Goldoft M, Wohrle R, et al. *Cryptococcus gattii* in the United States: clinical aspects of infection with an emerging pathogen. *Clin Infect Dis an Off Publ Infect Dis Soc Am*. 2011; 53: 1188–95.
5. Phillips P, Galanis E, MacDougall L, Chong MY, Balshaw R, Cook VJ, et al. Longitudinal clinical findings and outcome among patients with *Cryptococcus gattii* infection in British Columbia. *Clin Infect Dis an Off Publ Infect Dis Soc Am*. 2015; 60: 1368–76.
6. Kidd SE, Hagen F, Tscharke RL, Huynh M, Bartlett KH, Fyfe M, et al. A rare genotype of *Cryptococcus gattii* caused the cryptococcosis outbreak on Vancouver Island (British Columbia, Canada). *Proc Natl Acad Sci U S A*. 2004; 101: 17258–63.
7. Perfect JR, Casadevall A. Cryptococcosis. *Infect Dis Clin North Am*. 2002; 16: 837–74.
8. Marr KA. *Cryptococcus gattii*: the tip of the iceberg. *Clin Infect Dis an Off Publ Infect Dis Soc Am*. 2011; 53: 1196-8.
9. Chen SC-A, Slavin MA, Heath CH, Playford EG, Byth K, Marriott D, et al. Clinical manifestations of *Cryptococcus gattii* infection: determinants of neurological sequelae and death. *Clin Infect Dis an Off Publ Infect Dis Soc Am*. 2012; 55: 789–98.
10. Mitchell DH, Sorrell TC, Allworth AM, Heath CH, McGregor AR, Papanoum K, et al. Cryptococcal disease of the CNS in immunocompetent hosts: influence of cryptococcal variety on clinical manifestations and outcome. *Clin Infect Dis an Off Publ Infect Dis Soc Am*. 1995; 20: 611–6.
11. Lee SC, Dickson DW, Casadevall A. Pathology of cryptococcal meningoencephalitis: analysis of 27 patients with pathogenetic implications. *Hum Pathol*. 1996; 27: 839–47.
12. KA, Hall-Craggs MA, Miller RF, Kendall BE, Wilkinson ID, Paley MN, et al. The spectrum of MRI findings in CNS cryptococcosis in AIDS. *Clin Radiol*. 1996; 51: 842–50.
13. Cheng Y-C, Ling J-F, Chang F-C, Wang S-J, Fuh J-L, Chen S-S, et al. Radiological manifestations of cryptococcal infection in central nervous system. *J Chin Med Assoc*. 2003; 66: 19–26.
14. Franco-Paredes C, Womack T, Bohlmeier T, Sellers B, Hays A, Patel K, et al. Management of *Cryptococcus gattii* meningoencephalitis. *Lancet Infect Dis*. 2015; 15: 348–55.
15. Ngan NTT, Flower B, Day JN. Treatment of Cryptococcal Meningitis: How Have We Got Here and Where are We Going? *Drugs*. 2022; 82: 1237–49.