

Image is Hearts in The Large Bowel

Giovanna Giordano^{1*} and Elena Thai

Department of Medicine and Surgery Pathology Unit, University of Parma, Italy

Volume 1 Issue 2- 2018

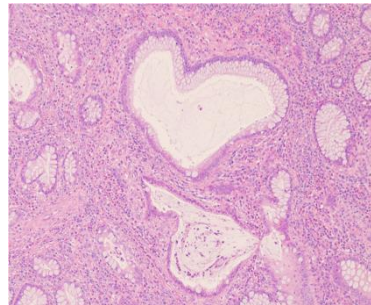
Received Date: 16 Aug 2018

Accepted Date: 28 Aug 2018

Published Date: 31 Aug 2018

1. Clinical Image

Biopsy of colon in a case of ulcerative recto-colitis stained with hematoxylin and eosin method showing a dilated colonic gland with the heart shape located near to a second more irregular, symmetric gland, as if this is an image reflected in a pond.



*Corresponding Author (s): Giovanna Giordano, Department of Medicine and Surgery Pathology Unit, University of Parma, Italy, Tel: +39 0521 702625; Email: giovanna.giordano@unipr.it or giovannagiordan@tiscali.it